

CHRISTIAN, DAVID MARION
674340/1315
DIED 2 JUN 1965 LTJG, USNR

MEDICAL RECORD UNCLASSIFIED

Reviewed by DPAA IAW DoDM 5400.07 and
P.L. 102-190, 105 Stat. 1290, 1480-1481
Date: 12 Mar 2024 Initials: RW

QC'd by DPAA
Date: 21 Mar 2024
Initials: CG

1771
N-642
Ser: 20003
30 Dec 86

Mrs. Ethel E. Christian
13450 Highway 8, Space 68
Lakeside, CA 92040

Dear Mrs. Christian:

Mr. John Rogers from over Naval Medical Command in Washington, D.C. asked that I send the enclosed data to you.

I trust you are well and hope that you and your family were able to get together over the holidays.

We'll be in touch soon.

Sincerely,

J. L. GREER JR.
Head, Casualty
Assistance Branch

Enclosure

Reviewed by DPAA IAW DoDM 5400.07 and
P.L. 102-190, 105 Stat. 1290, 1480-1481
Date: 12 Mar 2024 Initials: RW

QC'd by DPAA
Date: 21 Mar 2024
Initials: CG

▲ Fold and Detach Stub Here ▲

B 83586291

Service Guarantee:

If this shipment is mailed at designated USPS Express Mail service facilities on or before the specified deposit time for next day delivery to the addressee, it will be delivered to the addressee or agent by 3:00 p.m. of the next day. Upon application by the mailer at the Express Mail originating office, USPS will refund the postage for this shipment if it is not delivered by 3:00 p.m. of the next day, unless delivery was attempted but could not be made or this shipment was delayed by strike or work stoppage. See Domestic Mail Manual Chapter 2 for details.



Express Mail International Service mailings are not covered by this service guarantee. See the International Mail Manual for details.

Insurance Coverage:

See section 294 of the Domestic Mail Manual for exclusions of coverage.

(1) *Merchandise Insurance.* Merchandise is insured against loss, damage or rifling up to a maximum of \$500. Indemnity will not be paid for spoilage of perishable items.

(2) *Document Reconstruction Insurance.* Non-negotiable documents are insured against loss, damage or rifling up to \$50,000 per piece subject to a limit of \$500,000 per occurrence.

- Signature is required upon delivery.
- Claims for delay, loss, damage or rifling must be made within 90 days. Claim forms may be obtained at the post office of mailing.
- The Customer Receipt must be presented when a claim is filed.

Customer:

Please tear off this stub and keep it for reference when depositing prepaid Express Mail Next Day Service shipments in Express Mail collection boxes or when giving prepaid Express Mail Next Day Service shipments to Postal Service delivery personnel. Affix the remaining label set to your shipment. For reference, write on this stub the date that the shipment was mailed (if deposited in an Express

Date Mailed: 12-30-86 **Initials:** JLG

Mail Collection Box, also initial the stub). Deadlines for deposit for next day delivery differ according to the destination. To ensure next day delivery consult your local Express Mail Directory

Postal Acceptance Employee:

After completing the "Origin" and "Acceptance" blocks on the mailing label, give this stub to the mailer along with the Customer Receipt copy.



ARMED FORCES INSTITUTE OF PATHOLOGY

WASHINGTON, D.C. 20306-6000



REPLY TO: THE DIRECTOR
ATTN: AFIP-RRR

PATIENT IDENTIFICATION		PLEASE USE AFIP ACCESSION NUMBER IN ALL CORRESPONDENCE	
AFIP ACCESSION NUMBER 2095792-4	CHECK DIGIT 4	SEQUENCE 0	
NAME CHRISTIAN, DAVID M. LTJG - 571-56-3259		SSAN	
SURGICAL/AUTOPSY PATH ACCESSION #S			
PLEASE INFORM US OF ANY PATIENT IDENTIFICATION ERRORS			

RRM/CJR/jl

Chief, ASGRO
U.S. Army Military Personnel Center
2461 Eisenhower Avenue
Alexandria, VA 22331-0400

DATE: 15 December 1986

CONSULTATION REPORT ON CONTRIBUTOR MATERIAL

AFIP DIAGNOSIS: Forensic Review--CILHI 0036-86

- Human skeletal remains returned to United States custody 11 April 1986; Hanoi, Socialist Republic of Vietnam.
- We cannot verify the stated correlation of crash site with location of remains recovery. We relied on the accuracy of the recorded anthropologic measurements and the radiographs and recorded dental charting in our review of the documents submitted.
- The anthropologic data for the associated skeletal remains is consistent with the available antemortem anthropomorphic information.
- No antemortem dental records except for an SF 88 exist in this case and no antemortem dental X-rays have been located. Taken in this context, the remains are consistent with those of David M. Christian, but they cannot be identified with certainty.

Review by:

Michael A. Clark
MICHAEL A. CLARK, Ph.D., M.D.
Commander, MC, USN
Chief, Division of Forensic Pathology

Robert R. McMeekin
ROBERT R. McMEEKIN, M.D.
Colonel, MC, USA
The Director

Reviewed by:

Charles J. Ruehle
CHARLES J. RUEHLE, M.D.
Colonel, USAF, MC SFS
Chairman, Department of Forensic Sciences

Reviewed by DPAA IAW DoDM 5400.07 and
P.L. 102-190, 105 Stat. 1290, 1480-1481
Date: 31 AUG 2021
Initials: RW

QC'd by DPAA
Date: 21 Mar 2024
Initials: CG

REPRODUCED AT CONSIDERABLE EXPENSE



2095792



DEPARTMENT OF THE ARMY
UNITED STATES ARMY CENTRAL IDENTIFICATION LABORATORY, HAWAII
FORT SHAFTER, HAWAII 96858-5480

1 December 1986

ANTHROPOLOGICAL NARRATIVE

I have examined the 70 mm chest x-ray identified to me as that of Christian, David M. I have compared this x-ray (with magnification) to the remains CILHI 0036-86. While there are no inconsistencies, none of the details that might be useful in positive identification remain undamaged in the skeletal remains. These details, such as the morphology of the spinous processes of the lower cervical vertebrae or the first few thoracic vertebrae are damaged in the CILHI 0036-86.

In my opinion, enhancement would not be useful or appropriate in this case.

(b)(6)

Forensic Anthropologist

Reviewed by DPAA IAW DoDM 5400.07 and
P.L. 102-190, 105 Stat. 1290, 1480-1481
Date: 12 Mar 2024 Initials: RW

QC'd by DPAA
Date: 21 Mar 2024
Initials: CG

2095792

THE UNIVERSITY OF TENNESSEE
KNOXVILLE



TO: [redacted] (b)(6)
FROM: [redacted] (b)(6) Tennessee State Forensic Anthropologist
SUBJECT: Review of identification documents on:
CHRISTIAN, DAVID M CILHI 0036-86
571-56-3259
Lt. JG USN
DATE: November 26, 1986

College of
Liberal Arts

Department of
Anthropology

On Tuesday, November 25, 1986, I received by Express Mail the identification documentation submitted by the U.S. Army Central Identification Laboratory, Hawaii (CILHI), along with the reports from [redacted] (b)(6) and [redacted] (b)(6) for CILHI 0036-86, Lieutenant, Junior Grade David M. Christian, 571-56-3259, USN.

On Wednesday, November 26, 1986, I carefully reviewed the documents submitted. These remains were received from North Vietnamese officials on 10 April 86 in a wooden box numbered 3. This is a relatively complete skeleton in good condition. The major areas for anthropological and anthropometric estimations of age (skull and pelvis), sex (pelvis and skull), race (skull) and stature (femur and tibia) are present. Techniques used for anthropological observations and estimations are consistent with standard procedure and result in data consistent with Lt. JG DAVID M. CHRISTIAN. Although handedness arrived at by Collins and Furue based on analysis of the skeleton as left handed does not match the recorded data (right handed) is not surprising. Handedness is a complicated process involving all of the joints in the arms and needs much more study before we as physical anthropologists can feel secure in our observations (see Glassman and Bass 1986:589-595).

If no before-death dental x-rays are present for comparison the standard procedure is to compare any photographs of the subject and look for similarities in dental morphology and tooth spacing. This is especially true in children who most often have no previous dental record. I agree with [redacted] (b)(6) that the dentition recovered as CILHI 0036-86 is similar with the features seen in photographs of DAVID M. CHRISTIAN.

In summary, I find no inconsistencies in the identification data and my professional opinion is that these remains are those of Lt. JG DAVID M. CHRISTIAN.

[redacted] (b)(6)

Diplomate, American Board of
Forensic Anthropology

Reviewed by DPAA IAW DoDM 5400.07 and
P.L. 102-190, 105 Stat. 1290, 1480-1481
Date: 12 Mar 2024 Initials: RW

QC'd by DPAA
Date: 21 Mar 2024
Initials: CG

REPRODUCED BY AUTHORITY OF THE SECRETARY OF DEFENSE



Reference

Glassman, David M. and William M. Bass
1986 Bilateral asymmetry of the long arm bones and jugular
foramen: Implications for handedness, Journal of
Forensic Sciences 31(2):589-595.

REDDONISTIN AT CONSTRUCTION EVIDENCE

Reviewed by DPAA IAW DoDM 5400.07 and
P.L. 102-190, 105 Stat. 1290, 1480-1481
Date: 12 Mar 2024 Initials: RW

QC'd by DPAA
Date: 21 Mar 2024
Initials: CG



FORENSIC CONSULTANT

(b)(6)

DIPLOMATE A.B.F.O.

(b)(6)

20 November 1986

Re: CILHI 0036-86

It has been recommended that the above case be identified as LTJG DAVID M. CHRISTIAN, 571-56-3259, USN.

I have examined all available dental evidence.

The only ante mortem dental chart consists of a SF 88 Type 2 dental examination done incident to a physical examination dated 15 March 1963. This chart is consistent with the dentition of CILHI 0036-86.

A facial photograph showing maxillary right and left central incisors, left lateral incisor, left canine, and part left first bicuspid and mandibular incisors is available for comparison. Maxillary left central incisor and mandibular right central incisor have been lost post mortem. Comparison of ante mortem photograph and post mortem photograph of the same area show similarities, and are consistent.

It is my opinion that the dentition of CILHI 36-86 is consistent with the known characteristics of LTJG DAVID M. CHRISTIAN but not identifying in and of itself. The dentition may be used in combination with other scientific reports to arrive at an opinion of identification with reasonable scientific certainty however.

(b)(6)

REPRODUCED AT GOVERNMENT EXPENSE

Reviewed by DPAA IAW DoDM 5400.07 and P.L. 102-190, 105 Stat. 1290, 1480-1481
Date: 12 Mar 2024 Initials: RW

QC'd by DPAA
Date: 21 Mar 2024
Initials: CG

8095 792



REPORT OF EXAMINATION

I have examined the case records of DAVID M. CHRISTIAN, LTJG, USN.

The skeletal charts and photographs indicate that the remains consist of a well-preserved and nearly complete skeleton. The portions used in determining age, sex, race and stature are all present. The methods used in making those determinations are all appropriate for these remains.

All available anthropological descriptions of these remains are consistent with the physical description of Lt. Christian. Handedness cannot be determined with a high degree of probability in purely skeletal remains. The nasal septum often becomes deviated to one side or the other after death by postmortem drying out of the thin plate of bone of which it is formed. As a result, postmortem descriptions of septum deviation are often not consistent with antemortem records. There is nothing in the anthropological narrative that excludes this identification.

I support the recommendation that these remains be identified as those of LtJg David M. Christian, based on the agreement of all available dental and anthropological evidence with similar data describing the deceased and the absence of any excluding factors.

November 8, 1985

(b)(6)

Diplomate, American Board
of Forensic Anthropology

Reviewed by DPAA IAW DoDM 5400.07 and
P.L. 102-190, 105 Stat. 1290, 1480-1481
Date: 12 Mar 2024 Initials: RW

QC'd by DPAA
Date: 21 Mar 2024
Initials: CG

RECORDED AT COMBATANT EVIDENCE



DEPARTMENT OF THE ARMY
UNITED STATES ARMY CENTRAL IDENTIFICATION LABORATORY, HAWAII
FORT SHAFTER, HAWAII 96858-5480



DAPC-PED-H


23 October 1986

SUBJECT: Proposed Identification of Remains CILHI 0036-86

Commander
Military Personnel Center
ATTN: DAPC-PED-F
Alexandria, VA 22331-0400

1. Forwarded for your review and evaluation are the processing charts, photographs and associated documentation to support the proposed identification CILHI 0036-86 as the remains of LTJG David M. CHRISTIAN, 571-56-3259, USN.
2. Upon completion of the ASGRO board action on this recommendation, request this office be advised of the identification decision and disposition instructions.
3. Also enclosed are all original medical records for LTJG CHRISTIAN for appropriate disposition by the parent service.

Encl (Dup)


JOHNIE E. WEBB, JR.
LTC, QM
Commanding

Reviewed by DPAA IAW DoDM 5400.07 and
P.L. 102-190, 105 Stat. 1290, 1480-1481
Date: 12 Mar 2024 Initials: RW

QC'd by DPAA
Date: 21 Mar 2024
Initials: CG

REPRODUCED AT GOVERNMENT EXPENSE



**PROCES-VERBAL
ON THE HANDING-OVER OF REMAINS
AND MATERIAL EVIDENCES OF THE U.S. PERSONNEL
WHO DIED DURING THE WAR IN VIETNAM**

1. Proceeding from the humane policy of the Government of the Socialist Republic of Vietnam, and as a sign of goodwill, on April 10, 1986, in Hanoi, the Vietnamese Office for Seeking Missing Personnel handed-over to representatives of the U.S. Government the recently recovered remains of twenty-one (21) American servicemen and the material evidences related three (3) others who died during the war in Vietnam and whose names are on the enclosed list.

2. The representatives of the U.S. Government received all remains of the above-mentioned twenty-one American servicemen and the material evidences related to three others and highly appreciated the humane policy and goodwill of the Government of the Socialist Republic of Vietnam.

Hanoi, April 10, 1986

Paul D. Metts
THE REPRESENTATIVE
OF THE U.S. GOVERNMENT

THE REPRESENTATIVE
OF THE VIETNAMESE OFFICE
FOR SEEKING MISSING PERSONNEL

Reviewed by DPAA IAW DoDM 5400.07 and
P.L. 102-190, 105 Stat. 1290, 1480-1481
Date: 12 Mar 2024 Initials: RW

QC'd by DPAA
Date: 21 Mar 2024
Initials: CG

[Handwritten signature]

RECORDED AT GOVERNMENT EVIDENCE

(2)

(3)

(4)

(5)

(6)

(7)

(8)

(9)

Reviewed by DPAA IAW DoDM 5400.07 and
P.L. 102-190, 105 Stat. 1290, 1480-1481
Date: 12 Mar 2024 Initials: RW

QC'd by DPAA
Date: 21 Mar 2024
Initials: CG



M TAB TAB TAB TAB

STATEMENT OF IDENTIFICATION

CILHI 0036-86 For use of this form, see AR 638-40; the proponent agency is MILPERCEN. REFNO 0092 1 01

NAME OF DECEASED (Last, First, MI) GRADE SSN BRANCH OF SERVICE DATE OF INCIDENT

CHRISTIAN, David M. LTJG 571-56-3259 USN 02 Jun 65

ORGANIZATION AND BASE PLACE OF DEATH/INCIDENT

VA-23 USS Midway CVA-41 Thanh Hoa Province, North Vietnam

CONDITION OF REMAINS (Describe briefly in Narrative below)

Table with 4 columns: Recognizable, Not Recognizable, Commingled, Mutilated. Includes rows for Burned, Decomposed, Semi-Skeletal, Skeletal.

MEANS OF IDENTIFICATION (Check all appropriate boxes. Specify supporting data in Narrative below)

Table with 4 columns: Fingerprint Comparison, Footprint Comparison, Dental Comparison (Visual), Anatomical Comparison. Includes rows for Skeletal Comparison, Personal Effects, Visual Recognition, Identification Tag(s), Other.

INCLOSURES

Table listing various forms: DD Form 565, DD Form 890, DD Form 891, DD Form 892, DD Form 893, DD Form 894, DD Form 897 (11), ID Card, DD Form 369, FD 258, AF Form 137, SF 603, Dental X-Rays PM, SF 88, SF 89, DD Form 898, SF 801, Photo (9), NAVMED N, Bio Data Sheet, SRV Proces-Verbal, For. Odont. Narr., DD Form 1300, Info-Plane Crash W/Map, SRV Info on List, Anthropol. Narr., DD Form 2064, Summary of Incident, Bright Light Narrative, Anthropometric Data Form.

NARRATIVE AND SUMMARY (Continue on reverse or use additional sheets, if required) X Anthropometric Data Form

CIRCUMSTANCES:

On 10 April 1986, a representative of "The Vietnamese Office for Seeking Missing Personnel" released to American authorities at Noi Bai Airport, Hanoi, SRV, 21 remains alleged to be those of Americans who died in Vietnam. Each of the 21 remains was enclosed in a wooden box bearing the number which corresponded to the official document provided by the SRV government. This document lists the presumed names, places, and dates of death of some of the decedents. Box 3 held this particular set of remains and the box number corresponded to the name CHRISTIAN DAVID M. on the official SRV list. On 11 April 1986, the remains arrived at the U.S. Army Central Identification Laboratory for processing, and Box 3 was assigned CILHI 0036-86.

CONDITION OF REMAINS:

The skeletal remains are in good condition, virtually complete and with a moderate amount of damage due to burial in soil. There are perimortem fractures of several bones and some postmortem erosion of cancellous bone on the articular surfaces. The skeletal remains of CILHI 0036-86 were not commingled with any other remains received in this repatriation.

PRIMARY METHOD OF IDENTIFICATION:

The primary means of identification are presumptive in nature. First, the forensic odontologist made a visual comparison of a full-face antemortem photograph of CHRISTIAN, David M. with the dental remains of CILHI 0036-86 and obtained highly favorable results. Secondly, antemortem photographs of LTJG CHRISTIAN showing dentition were visually compared by the Senior Physical Anthropologist with photographs of the well-preserved dental remains of CILHI 0036-86; an excellent match of cranio-facial and dental structures resulted. These results are discussed in detail in the Forensic Odontology Narrative. The dental remains CILHI 0036-86 were in good condition and contained many restorations; there are, however, no antemortem dental xrays or records available for LTJG CHRISTIAN. The dental remains of CILHI 0036-86 were also compared with the records of all other MIA/BNR in the CILHI composite antemortem dental data base, using the CAPMI (Computer Assisted Post

Antemortem (identification) system. No dental match could be made between CILHI 0036-86 and any other individual on the MIA/BNR rosters in the CILHI composite antemortem dental data base.

SUPPORTIVE EVIDENCE:

The physical characteristics of CILHI 0036-86 are consistent with what is known about LTJG CHRISTIAN. The skeletal remains of CILHI 0036-86 were compared with the records of all individuals from other incidents within a 20-mile diameter circle search (a total of 10 individuals; see accompanying DD Forms 897).

<u>SUMMARY</u>	POSTMORTEM FINDINGS- CILHI 0036-86	VERSUS	RECORDED DATA CHRISTIAN, David M.
RACE	Caucasoid		Caucasian
SEX	Male		Male
AGE	22 - 25 years		24 yrs, 04 mos, 17 dys
STATURE	67.2" +/-1.2"		66 3/4"
MUSCULARITY/BUILD	Slight-Average		Slender
HANDEDNESS	Left		Right
HEALED FRACTURES	None observed		None listed
PATHOLOGIES	Possible healed trauma on rt frontal above orbit & lateral to rt frontal eminence		1/2" scar on rt frontal; "permanent bump on forehead above rt eye"
PECULIARITIES	Septal deviation		None listed

RECOMMENDATIONS

Based on the strong presumptive evidence for identification of CILHI 0036-86 as CHRISTIAN, David M., to the exclusion of all others from the same repatriation, within the circle search area and in the CAPMI system, the favorable agreement of the physical anthropology of CILHI 0036-86 with available records of LTJG CHRISTIAN, the agreement of the date and location of the incident involving CHRISTIAN with information provided by SRV documents, and having no contradictory evidence, it is recommended that these remains be accepted as:

CHRISTIAN, David M.
571-56-3259
LTJG USN

RECOMMENDATIONS PRESENTED

TYPED NAME OF IDENTIFICATION SPECIALIST (b)(6)		NAME AND ADDRESS OF INSTALLATION U.S. Army Central Identification Laboratory Ft. Shafter, Hawaii 96858-5840	
TITLE OF IDENTIFICATION SPECIALIST Physical Anthropologists			
DATE 23 October 1986	(b)(6)		
To the best of my knowledge and belief, the statements made herein are correct and true.			
TYPED NAME & GRADE OF APPROVING OFFICER Johnie E. Webb, Jr., LTC, QM		NAME AND ADDRESS OF INSTALLATION U.S. Army Central Identification Laboratory Ft. Shafter, Hawaii 96858-5840	
TITLE OF APPROVING OFFICER Commander			
DATE 24 October 1986	SIGNATURE OF APPROVING OFFICER <i>Johnie E. Webb, Jr.</i>		

Reverse of DA Form 2773-R, Sep 84



RECORD OF IDENTIFICATION PROCESSING
(Effects and Physical Data)

DATE

23 October 1986

LAST NAME - FIRST NAME - MIDDLE INITIAL (Or unknown number)

CHRISTIAN, David M.

GRADE

LTJG

SERVICE NO. (344)

67 4340
571-56-3259

CIL CASE NUMBER (If applicable)

CILHI 0036-86

NAME OF CEMETERY, EVACUATION NUMBER, OR SEARCH AND RECOVERY NUMBER

PLOT


ROW

GRAVE

RECEIVED FROM

SRV Officials, Noi Bai Airport, Hanoi, SRV

IMPRINT OF IDENTIFICATION TAG



OFFICIAL IDENTIFICATION FOUND WITH REMAINS (Include personal effects aiding identification)

None received

ITEMS OF CLOTHING AND EQUIPMENT FOUND WITH REMAINS (Indicate type, color, size, markings, service, etc. If laundry marks are indistinct, follow procedures outlined in TM 10-286)

None received

Reviewed by DPAA IAW DoDM 5400.07 and
P.L. 102-190, 105 Stat. 1290, 1480-1481
Date: 12 Mar 2024 Initials: RW

QC'd by DPAA
Date: 21 Mar 2024
Initials: CG

FINGERPRINTS TAKEN

YES NO

X-RAYS MADE

YES NO

FLUOROSCOPE STATEMENT ATTACHED

YES NO

PHOTOGRAPHS TAKEN

YES NO

ANTHROPOLOGICAL STATEMENT MADE

YES NO

CHEMICAL STATEMENT ATTACHED

YES NO

PHYSICAL DESCRIPTION

ESTIMATED HEIGHT

67.2" +/- 1.2"

MUSCULARITY

Slight-Average

COLOR OF HAIR

None found

RACE OR NATIVITY

Caucasoid

TATTOOS, SCARS OR MARKS ON BODY

N/A

EVIDENCE OF HEALED FRACTURES AND BONE MALFORMATIONS

Possible healed trauma on right frontal

WOUNDS OR INJURIES

Multiple perimortem fractures

I HAVE PERSONALLY VIEWED THE REMAINS OF THIS DECEASED AND ALL RESULTING INFORMATION HAS BEEN RECORDED TO THE BEST OF MY KNOWLEDGE.

NAME, GRADE, AND ORGANIZATION

(b)(6)
Physical Anthropologist

(b)(6)

DD FORM 890
1 JAN 81

PREVIOUS EDITION OF THIS FORM IS OBSOLETE

☆ U S GOVERNMENT PRINTING OFFICE 1982-564-036 0215

CILHI 0036-86

DENTAL CHART

LAST NAME - FIRST NAME - MIDDLE INITIAL (or unknown number)											GRADE		SERVICE NO./SOCIAL SECURITY ACCT NO.		
CHRISTIAN, David M.											LTJG		674340 571-56-3259		
NAME OF CEMETERY, EVACUATION NUMBER, OR SEARCH AND RECOVERY NUMBER											PLOT		ROW	GRAVE	

MARKING ABBREVIATIONS:

<i>F-Facial</i>	<i>O-Occlusal</i>	<i>D-Distal</i>	<i>A'-Analgn</i>	<i>-Fill-Filling</i>	<i>Porc-Porcelain</i>	<i>Back-Backing</i>
<i>L-Lingual</i>	<i>M-Mesial</i>	<i>I-Incisal</i>	<i>CR-Crown</i>	<i>Plas-Plastic</i>	<i>Sil-Silicate</i>	<i>Fac-Facing</i>

CARIES																CARIES	
	RESTORATIONS	O-AM	O-AM	F-AM L-AM O-AM	MO-AM	MOD-AM	D-Sil M-Sil	L-AM	M-Sil L-AM D-Sil		ML-Sil -AM D-Sil	M-Sil L-AM	O-AM	O-AM	O-Prep		O-Prep
	1	2	3	4	5	6	7	8	9	10	11	12	13	14	15	16	
UPPER RIGHT																	UPPER LEFT
LOWER RIGHT																	LOWER LEFT
RESTORATIONS	HORIZONTAL IMPACTION	F-AM O-AM	F-AM MOF-AM	O-AM	O-AM								MOD-AM	F-AM MO-AM	F-AM F-AM O-AM	HORIZONTAL IMPACTION	RESTORATIONS
CARIES																	CARIES

THE FOLLOWING CONDITIONS WILL BE INDICATED IF PRESENT (Describe in detail in Remarks section)

<input type="checkbox"/> MOTTLED ENAMEL	<input type="checkbox"/> ROTATION	<input checked="" type="checkbox"/> FRACTURED ENAMEL	<input checked="" type="checkbox"/> IRREGULARITY OF ALIGNMENT
<input type="checkbox"/> ENAMEL HYPOPLASIA	<input type="checkbox"/> UNERUPTED TEETH	<input checked="" type="checkbox"/> FRACTURES OF TEETH	<input checked="" type="checkbox"/> UNUSUAL RESTORATIONS
<input type="checkbox"/> EROSION	<input type="checkbox"/> MALOCCLUSION	<input type="checkbox"/> RETAINED DECIDUOUS TEETH	<input type="checkbox"/> UNUSUAL APPLIANCES
<input type="checkbox"/> ABRASION	<input type="checkbox"/> SUPERNUMERARY TEETH	<input type="checkbox"/> ABNORMAL INTERDENTAL SPACES	<input type="checkbox"/> MALPOSED TEETH

Forensic Odontologist (b)(6) Senior Anthropologist (b)(6)

DD FORM 1 FEB 66 891

THIS IS OBSOLETE (for Army use only).

2095 792

REPRODUCTION AT GOVERNMENT EXPENSE

REMARKS (If no abnormalities are found make notation to that effect)

UNUSUAL Restoration:

Tooth #8 - Root canal fill (Gutta Percha)
 Tooth #10 - Root canal fill (Gutta Percha)

Irregularity of alignment -

Tooth #27 - Rotated 45 degrees to the distal

Fractures of ENAMEL -

Tooth #30 - ML Cusp fx'd and not recovered

Fractures of Teeth -

Tooth #14 - Crown fractured off and not recovered
 Tooth #31 - Occlusal amalgam fx'd and not recovered

EXAMPLE METHOD OF PREPARATION

	1	2	3	4	5	6	7	8	9	10	11	12	13	14	15	16	
UPPER RIGHT																	UPPER LEFT
	1. O-AM	2. DOL-AM; F-AM	3. MOD GOLD FILL	4. F-GOLD FILL; ML-AM	5. NO-AM	6. ML-GOLD FILL	7. 3/4 GOLD CR	8. D-PORC FILL	9. PORC-CR	10. F-PORC FILL; L-AM	11. MF-PORC FILL	12. PX-POSTHUMOUSLY MISSING	13. GOLD-CR	14. MISSING	15. NO-AM; L-AM	16. MODL-AM	



DEPARTMENT OF THE ARMY
UNITED STATES ARMY CENTRAL IDENTIFICATION LABORATORY, HAWAII
FORT SHAFTER, HAWAII 96858-5480

DARC-PED-H

10 Oct 1986

FORENSIC ODONTOLOGY NARRATIVE: CILHI 0036-86

On April 11, 1986, these remains were returned to the United States from the Socialist Republic of Vietnam. They are described diagrammatically on DD Form 891.

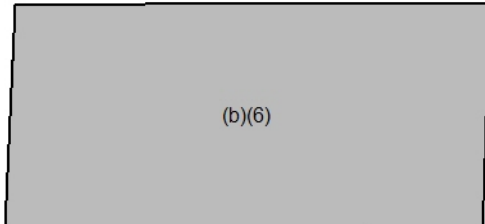
The condition of these remains can be described as excellent.

Although no antemortem dental records or radiographs were available for the individual whose remains these were believed to be, CHRISTIAN, David M., an antemortem photograph was available for analysis. A visual comparison of this photograph with the postmortem dental remains was highly favorable. Comparison of the relative positions of each tooth postmortem, in relation to the adjacent teeth, produced no inconsistencies. Tooth #25 (mandibular right central incisor) is facially displaced in the antemortem photograph, but was not recovered postmortem so a direct comparison is not possible. However, the positions of the interproximal wear facets are observed to be displaced to the facial and more apical than normal on the distal of tooth #24 (mandibular left central incisor) and the mesial of tooth #26 (mandibular right lateral incisor). The position of the socket for tooth #25 is in a more facial position in relation to the sockets of teeth #24 and #26. While minor variations in size may exist between bilaterally similar teeth, the interproximal space between teeth #24 and #26 measures 1.1 mm less than the mesial-distal width of tooth #24, the bilateral counterpart of the missing tooth #25. This discrepancy implies that tooth #25 must have been rotated, or displaced to the facial or lingual. There was no rotation of the socket for this tooth. All of these observations are consistent with the postmortem missing tooth #25 having been facially displaced as in the antemortem photograph of CHRISTIAN.

The unusual incisal edge angulation, down and toward the distal, observed in the mandibular incisors is significantly consistent between the remains and the antemortem photograph. This is an uncommon morphologic variation from what is normally observed in mandibular incisors.

A computerized comparison of these remains against the CILHI MIA/BNR composite antemortem dental data base, utilizing the Computer Assisted Postmortem Identification (CAPMI) system, produced no possible matches. Again, there were no antemortem dental records available to enter into the system for CHRISTIAN.

I therefore find the remains designated CILHI 0036-86 to be consistent with the information available for CHRISTIAN, David M., SSN 571-56-3259, LTJG, USN, and recommend they be so identified.



(b)(6)

REPRODUCED AT GOVERNMENT EXPENSE

RECORD OF IDENTIFICATION PROCESSING
SKELETAL CHART

CILHI 0036-86

BLACK OUT PORTIONS NOT RECOVERED

LAST NAME - FIRST NAME - MIDDLE INITIAL (or unknown number)
CHRISTIAN, David M.

GRADE: **LTJG** SERVICE NUMBER / SSN: **674340 / 571-56-3259**

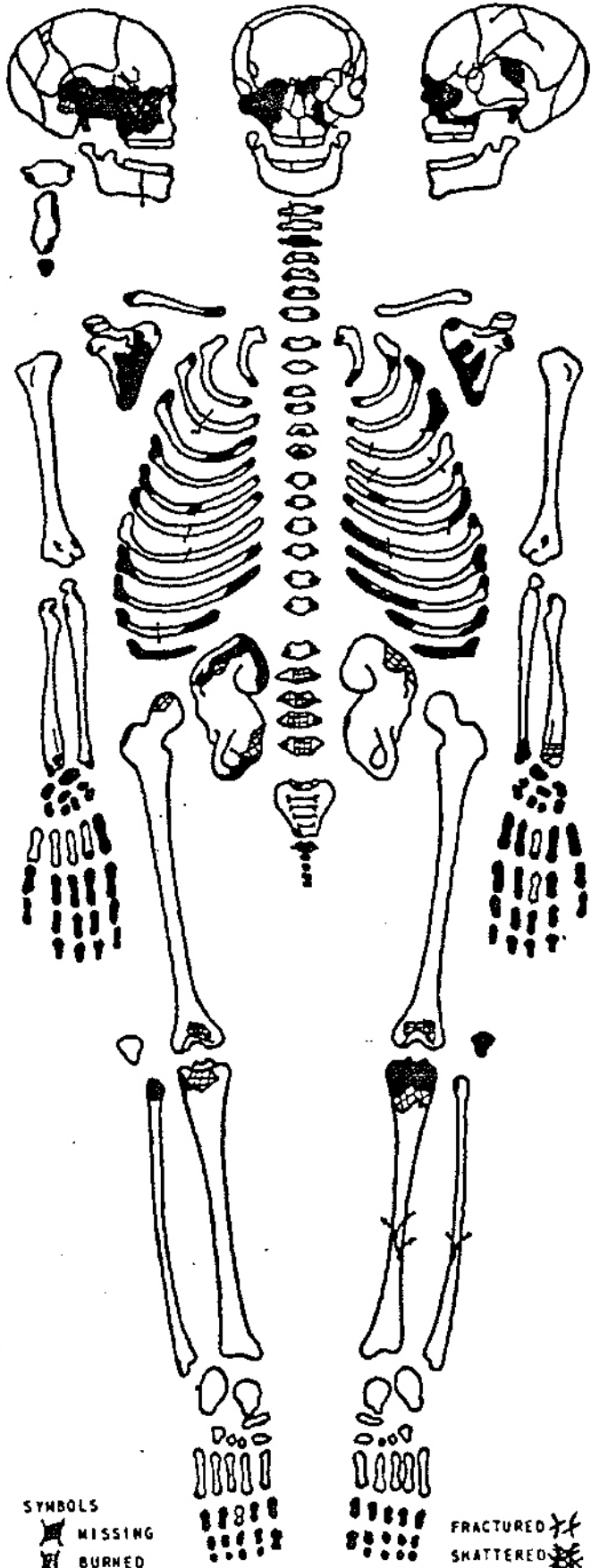
NAME OF CEMETERY, EVACUATION NUMBER, OR SEARCH AND RECOVERY NUMBER

PLOT: _____ ROW: _____ GRAVE: _____

ESTIMATED AGE (Years): **22 - 25** ESTIMATED HEIGHT: **Fem & Tib 67.2" ± 1.2"**

SKELETAL MEASUREMENTS (Centimeters)

SKELETAL MEMBER	METHOD	RIGHT	LEFT
SKULL			
NUMERUS	Max. L.	31.6	31.5
ULNA		-	-
RADIUS	Max. L.	-	24.6
FEMUR	Max. L.	-	46.2
TIBIA	Max. L.	36.5	-
FIBULA		-	-



REMARKS OR STATEMENT OF ANTHROPOLOGIST (Continue on reverse if more space is required)

CONDITION OF REMAINS: Remains are in good condition with moderate postmortem damage. Some evidence of burial in soil.

RACE: **Caucasoid**
SEX: **Male**
HANDEDNESS: **Left**
MUSCULARITY: **Slight - Average**
HEALED FRACTURES: **None evident**
PATHOLOGIES: **Possible healed trauma on Rt frontal above orbit**
PECULIARITIES: **Septal deviation**

THE PARTS PRESENT AS INDICATED ON THIS SKELETAL CHART REPRESENTS ONE AND THE SAME INDIVIDUAL

PHYSICAL ANTHROPOLOGIST (Name)

(b)(6)

SYMBOLS
 MISSING
 BURNED
 FRACTURED
 SHATTERED

DD Form 892, Record of Identification Processing, Continuation Sheet 1 of 5
CILHI 0036-86, CHRISTIAN, David M.

Box 3 of the 10 April 1986 turnover contained the skeletal remains assigned the processing number CILHI 0036-86. The name associated with these remains by the SRV was CHRISTIAN DAVID M.

The remains of CILHI 0036-86 are in good condition, and have sustained a moderate amount of postmortem damage. Several infracranial bones (first cervical vertebra, left tibia and fibula) have perimortem fractures. There is some postmortem destruction of cancellous bone in the articular ends of the long bones, vertebral transverse processes, and innominates. The skeleton appears to have been buried in a non-acidic or only slightly acidic soil; in fact, the soil sample taken from the left tibia is a sandy loam. Greenish stains (possibly from contact with copper-based metal) appear on the following bones: mandible, left clavicle, sternebra 4, left 5th rib, right 1st metacarpal, right ilium, distal right femur, and the midshaft of the left femur.

The skeletal remains of CILHI 0036-86 are virtually complete, lacking only portions of the facial skeleton and the basicranium, the third cervical vertebra, the right and left 12th ribs, and some hand and foot bones. No other individual's skeletal remains were commingled with those of CILHI 0036-86 nor was bone articulating with elements of CILHI 0036-86 segregated from any other individual in this repatriation. The occipital portion of CILHI 0036-86 articulates with atlas, all elements of the vertebral column and pelvic girdle articulate as well, as do the intact major joints of the appendicular skeleton (the shoulder, elbow and hip joints, the right knee, and the right and left ankle joints). The cranial and infracranial bones of CILHI 0036-86 thus belong to one individual.

SKELETAL ANALYSIS

RACE: (Caucasoid)

There is nothing dentally or skeletally to suggest other than a Caucasoid ancestry for CILHI 0036-86. The rounded cranial vault with its high, straight forehead, complex sutures, obvious muscle markings and strong mastoids is typically Caucasoid in appearance. Available portions of the facial skeleton are also strongly indicative of Caucasoid ancestry (the receding malar, sharp lower nasal border and margins) as is the mandible, with its undulating inferior border and "waisted", sloping ascending rami. Both maxillae and the mandible of CILHI 0036-86 present the triangular dental arches characteristic of Caucasoids. The infracranial skeleton has the broad pelvic basin and the moderate anterior bowing of the femora typically observed in someone of Caucasoid ancestry.

AGE: (22 - 25)

Many of the standard criteria used in ageing young adults were present in the well-preserved skeleton of CILHI 0036-86. The left pubic symphysis could be aged at Todd Stage III (22 - 24 years) or a combined McKern & Stewart score of 7 (3 - 3 - 1) which correlates to an age range of 20 - 24

REPRODUCED AT GOVERNMENT EXPENSE



DD Form 892, Record of Identification Processing, Continuation Sheet 2 of 5
CILHI 0036-86, CHRISTIAN, David M.

years, a mean age of 22.42 years. Ageing information obtained from several regions of the skeleton of CILHI 0036-86 generally supports the age assessments made by using the pubic symphysis. The spheno-occipital synchondrosis of CILHI 0036-86 is completely fused, an event which occurs between 17/18 and 22 years. The medial clavicular epiphyses are at Stage 2 which ranges from 18/19 to 24/25 years. The superior and inferior surfaces of the vertebral centra are at Stage 3 (age range, 17/18 - 23) while the vertebral spines are completely fused, or at Stage 4 (age range 17/18 - 24/25). The rib heads of CILHI 0036-86 are completely fused and the age range for this site is 18 to 24. The sacrum of CILHI 0036-86 shows a completely fused S2-S3 joint (age range 17/18 - 24) and a recently fused S1-S2 joint (age range 17/18 - 33). The other, major late-fusing epiphyses (i.e., iliac crest, ischium, medial epicondyle of humerus, distal radius, humeral and femoral heads) are all completely fused with no signs of recent union. Taken together, these stages of epiphyseal union indicate an age range of 22 to 25 years as being most appropriate for CILHI 0036-86.

HANDEDNESS: (Left)

The areas most useful for assessing handedness -- the dorsal margins of the glenoid cavities on the right and left scapulae -- are present in CILHI 0036-86. The left scapula clearly shows greater beveling of the dorsal margin. In addition, the muscle attachments, markings and ridges are greater on the left humerus, radius and ulna than on the right; the joint surfaces of the left elbow are more developed than on the right.

MUSCULARITY: (Slight-Average)

The muscle attachments and ridges of the long bones and major joints show a slighter-than-average development.

HEALED FRACTURES: (None observed)

No evidence of a healed, antemortem fracture was observed in the skeleton of CILHI 0036-86.

PATHOLOGIES: (Possible healed trauma on right frontal bone)

The right frontal bone of CILHI 0036-86 has two areas of healed bone -- suggestive of antemortem trauma -- above the right orbit and lateral to the right frontal eminence. A groove (about 2.2 cm long) lies about 4.1 cm above the right supra-orbital foramen. Additionally, there is a small circular depression about 3.5 cm above the right supraorbital foramen and medial to the groove. Both bony scars have healed edges and are clearly of antemortem origin. Accompanying photographs illustrate these areas of possible healed trauma on the right frontal of CILHI 0036-86.



DD Form 892, Record of Identification Processing, Continuation Sheet 3 of 5
CILHI 0036-86, CHRISTIAN, David M.

PECULIARITIES (Septal deviation)

The maxillary portions of CILHI 0036-86 still have part of the nasal septum, which appears to have been deviated. Postmortem damage to the maxillae, however, has made it impossible to determine whether the septal deviation was left or right.

STATURE: (66 to 68.4")

A stature estimation for CILHI 0036-86 was calculated by using the maximum lengths of the femur and tibia in the standard regression equations developed by Trotter for adult Caucasian males. This stature estimation is calculated for CILHI 0036-86 as follows:

$$1.3(46.2 + 36.5) + 63.29 \pm 2.99 \text{ cm} = 170.8 \text{ cm} \pm 2.99 \text{ cm}$$
$$\text{or} \quad 67.2" \pm 1.2"$$

EVALUATION

When the forensic odontologist visually compared antemortem photographs of the dentition of CHRISTIAN, David M. with the dental remains of CILHI 0036-86, he obtained a highly favorable comparison of dental structures. Further visual comparison by the Senior Physical Anthropologist of antemortem photographs of CHRISTIAN with photographs of the dental remains of CILHI 0036-86 produced an excellent match of cranio-facial and dental structures. (See FORENSIC ODONTOLOGY NARRATIVE for complete discussion of the visual comparison of the antemortem and postmortem dentitions.) Furthermore, dental data on the ten individuals in the 20-mile diameter circle search indicate absolute mismatches with the dentition of CILHI 0036-86 -- nine individuals by antemortem dental xrays and the tenth by antemortem dental records.

Antemortem medical data on the individuals in the circle search area also indicate mismatches -- in every instance -- with the physical characteristics of the skeleton of CILHI 0036-86. The following table presents a comparative summary of the physical characteristics of CILHI 0036-86, LTJG CHRISTIAN and the ten associated cases in the circle search; the excluding factors are printed in boldface. As can be seen, recorded heights for nine of the ten individuals in the circle search area fall outside the stature range calculated for CILHI 0036-86. Several people may be excluded on the bases of significantly different ages-at-incident or antemortem, healed fractures. In general, every associated case possesses at least one excluding physical factor in addition to contradictory antemortem dental data.

REPRODUCED AT GOVERNMENT EXPENSE

Reviewed by DPAA IAW DoDM 5400.07 and
P.L. 102-190, 105 Stat. 1290, 1480-1481
Date: 12 Mar 2024 Initials: RW

QC'd by DPAA
Date: 21 Mar 2024
Initials: CG

3095 792

DD Form 892, Record of Identification Processing, Continuation Sheet 4 of 5; CILHI 0036-86, CHRISTIAN, David M.
 EXCLUSION CHART

INDIVIDUAL (REFNO)	STATURE	AGE	MUSCULARITY/ BUILD	HANDEDNESS	HEALED FRACTURES	PATHOLOGIES	PECULIARITIES	ANTEMORTEM DENTAL DATA
CILHI 0036-86	66.1"*- 68.4"*	22-25	Slight- Average	Left	None observed	Possible trauma on rt frontal	Septal deviation	
CHRISTIAN, David M. (REFNO 0092 1 01)	66 3/4"	24	Slender	Right	None listed	1/2" scar & permanent bump on rt frontal	None listed	None available
MCMICAN (REFNO 0093 1 01)	69"	24	Medium	Right	None listed	None listed	None listed	Records
AMSPACHER (REFNO 0093 1 02)	70"	20	Medium	Right	Arm & wrist (Age 7)	None listed	None listed	Xrays & Records
ROMANO (REFNO 0093 1 03)	72"	23	Medium	Not listed	None listed	None listed	None listed	Xrays & Records
PLANTS (REFNO 0093 1 04)	68"	25	Medium	Right	None listed	None listed	Pes planus 2 ⁰	Xrays & Records
HOGAN (REFNO 0578 0 01)	71"	26	Medium	Right	None listed	None listed	Lt septal deviation	Xrays & Records
DRAEGER (REFNO 0067 1 01)	72"	31	Medium	Right	None listed	None listed	None listed	Xrays & Records
KOONS (REFNO 1789 1 01)	69"	25	Medium - Heavy	Left	None listed	None listed	None listed	Xrays & Records
STOLZ (REFNO 1789 1 02)	70"	26	Medium	Right	None listed	None listed	Pes planus	Xrays & Records
COAKLEY (REFNO 0457 0 01)	71.5"	33	Medium	Right	Lt skull, Lt clavicle & lt ribs	None listed	None listed	Xrays & Records

(b)(3): P. L. 102-190 105 Stat. 1290 1480-1481

* The range of the stature estimation for CILHI 0036-86 uses one standard deviation (+/- 1.2").

Reviewed by DPAA IAW DoDM 5400.07 and
 P.L. 102-190, 105 Stat. 1290, 1480-1481
 Date: 12 Mar 2024 Initials: RW

QC'd by DPAA
 Date: 21 Mar 2024
 Initials: CG



3095 133



DD Form 892, Record of Identification Processing, Continuation Sheet 5 of 5
CILHI 0036-86, CHRISTIAN, David M.

The physical characteristics of CILHI 0036-86 are quite compatible with available antemortem data on CHRISTIAN, David M., especially those of age, stature, muscularity and pathology.

REPRODUCED AT GOVERNMENT EXPENSE

	CILHI 0036-86	CHRISTIAN, David M.
Age	22 - 25 years	24 yrs, 04 mos, 17 dys
Stature	67.2" +/- 1.2"	66 3/4"
Sex	Male	Male
Race	Caucasoid	Caucasian
Muscularity/Build	Slight-Average	Slender
Handedness	Left	Right
Healed Fractures	None evident	None listed
Pathologies/Scars	Possible healed trauma on rt frontal above orbit & lateral to frontal eminence	1/2" scar on rt frontal; "permanent bump on forehead above rt eye"
Peculiarities	Septal deviation	None listed

The finding of left-handedness for CILHI 0036-86 contradicts the medical records of LTJG CHRISTIAN which list him as right-handed. Plausible explanations for this discrepancy exist, and include the possibility that LTJG CHRISTIAN wrote with his right hand but used the left hand -- and shoulder and elbow -- in athletic or other strenuous activities.

The recorded age-at-incident for LTJG CHRISTIAN falls within the age range determined for CILHI 0036-86; the muscularity assessment of "Slight-Average" for CILHI 0036-86 fits with the antemortem data on CHRISTIAN, whose medical records describe him as having had a slender build. The findings of possible antemortem, healed trauma on the right frontal of CILHI 0036-86 correlate well to the 1/2" scar on the right frontal noted in LTJG CHRISTIAN's medical records and to the information from LTJG CHRISTIAN's family stating that he had a "permanent bump on the forehead above the right eye" (cf. COMNAVMILPERSCOM MSG DTG 222122Z May 86).

The dentition, cranial and infracranial bones of CILHI 0036-86 are the remains of one person. The results of the visual dental comparison and the photographic comparison of antemortem and postmortem facial/dental structures, and the corroborative findings of the anthropological analysis of the skeleton of CILHI 0036-86 indicate that that person is LTJG David M. CHRISTIAN.

Narrative Prepared By:

Narrative Verified By:



(b)(6)

Physical Anthropologist

Senior Physical Anthropologist

PHYSICAL AND DENTAL COMPARISON CHART

REFNO: 0092



REMAINS OF		NAME	
CILHI 0036-86		CHRISTIAN, David M. 571-56-3259 LTJG USN	
1	O-AM	1	
2	O-AM	2	
3	O-AM, F-AM, L-AM	3	
4	MO-AM	4	
5	MOD-AM	5	
6	M-Sil, D-Sil	6	Caries
7	L-AM	7	
8	M-Sil, D-Sil, L-AM	8	Caries
9	PX	9	
10	ML-Sil, D-Sil, L-AM	10	
11	M-Sil, L-AM	11	
12	O-AM	12	
13	O-AM	13	
14	Crown Fx'd, O-Prep	14	Caries
15	O-Prep, O-Prep	15	Caries
16		16	
17	Horizontal impaction	17	
18	O-AM, F-AM, F-AM	18	Caries
19	MO-AM, F-AM	19	
20	MOD-AM	20	
21		21	
22		22	
23		23	
24		24	
25	PX	25	
26		26	
27		27	
28	O-AM	28	
29	O-AM	29	
30	MOF-AM, F-AM	30	Caries
31	O-AM, F-AM	31	
32	Horizontal impaction	32	
ESTIMATED HEIGHT 67.2 + 1.2"		HEIGHT 66 3/4" SITTING HEIGHT: 36"	
XXXXXXXXXXXX MUSCULARITY: Slight-average		WEIGHT 125 lb BUILD: Slender	
ESTIMATED AGE 22 - 25 years		AGE 24yrs, 04mos, 17dys DOI: 02 Jun 65 DOB: 15 Jan 41	
HAIR None found		HAIR Brown	
REMARKS RACE: Caucasoid SEX: Male HANDEDNESS: Left HEALED FRACTURES: None observed PATHOLOGIES: Possible healed trauma on Rt frontal above orbit PECULIARITIES: Septal deviation		REMARKS RACE: Caucasian SEX: Male BLOOD TYPE: O Pos HANDEDNESS: Right SCARS: 1 1/2" right patella 1" occipital 1" right elbow 1/2" right frontal HEALED FRACTURES: None listed PECULIARITIES: None listed	

Reviewed by DPAA IAW DoDM 5400.07 and P.L. 102-190, 105 Stat. 1290, 1480-1481 Date: 12 Mar 2024 Initials: RW

QC'd by DPAA Date: 21 Mar 2024 Initials: CG

PHYSICAL AND DENTAL COMPARISON CHART

REFNO: 0093



REMAINS OF		NAME	
CILHI' 0036-86		McMICAN, M. D. 534-34-5803 LTJG USN	
1	O-AM	<input checked="" type="checkbox"/>	
2	O-AM	<input checked="" type="checkbox"/>	2 MOL-AM
3	O-AM, F-AM, L-AM	<input checked="" type="checkbox"/>	3 MO-AM, O-AM
4	MO-AM	<input checked="" type="checkbox"/>	
5	MOD-AM	<input checked="" type="checkbox"/>	5
6	M-Sil, D-Sil	<input checked="" type="checkbox"/>	6 F-AM/Sil, M-Sil
7	L-AM	<input checked="" type="checkbox"/>	7 M-Sil, D-Sil
8	M-Sil, D-Sil, L-AM	<input checked="" type="checkbox"/>	8 MI-Sil, D-Sil
9	PX	<input checked="" type="checkbox"/>	9 M-Sil
10	ML-Sil, D-Sil, L-AM	<input checked="" type="checkbox"/>	10
11	M-Sil, L-AM	<input checked="" type="checkbox"/>	11
12	O-AM	<input checked="" type="checkbox"/>	12 DO-AM
13	O-AM	<input checked="" type="checkbox"/>	13 DO-AM
14	Crown Fx'd, O-Prep	<input checked="" type="checkbox"/>	
15	O-Prep, O-Prep	<input checked="" type="checkbox"/>	15 MO/O-AM, OL-AM
16		<input checked="" type="checkbox"/>	
17	Horizontal impaction	<input checked="" type="checkbox"/>	
18	O-AM, F-AM, F-AM	<input checked="" type="checkbox"/>	18 MO-AM
19	MO-AM, F-AM	<input checked="" type="checkbox"/>	19 DO-AM, F-AM
20	MOD-AM	<input checked="" type="checkbox"/>	Rem Ptr Dtr
21		<input checked="" type="checkbox"/>	21 DO-AM
22		<input checked="" type="checkbox"/>	22
23		<input checked="" type="checkbox"/>	23
24		<input checked="" type="checkbox"/>	24
25	PX	<input checked="" type="checkbox"/>	25
26		<input checked="" type="checkbox"/>	26
27		<input checked="" type="checkbox"/>	27
28	O-AM	<input checked="" type="checkbox"/>	28 MO/MOD-AM
29	O-AM	<input checked="" type="checkbox"/>	29 MO-AM
30	MOF-AM, F-AM	<input checked="" type="checkbox"/>	Rem Ptr Dtr
31	O-AM, F-AM	<input checked="" type="checkbox"/>	31
32	Horizontal impaction	<input checked="" type="checkbox"/>	
ESTIMATED HEIGHT 67.2 + 1.2"		HEIGHT 69" SITTING HEIGHT; 36 1/2"	
XXXXXXXXXXXX MUSCULARITY: Slight-average		WEIGHT 163 lb BUILD: Medium	
ESTIMATED AGE 22 - 25 years		AGE 24yrs, 05mos, 03dys DOI: 02 Jun 65 DOB: 29 Dec 40	
HAIR None found		HAIR Brown	
REMARKS RACE: Caucasoid SEX: Male HANDEDNESS: Left HEALED FRACTURES: None observed PATHOLOGIES: Possible healed trauma on Rt frontal above orbit PECULIARITIES: Septal deviation		REMARKS RACE: Caucasian SEX: Male BLOOD TYPE: A Pos HANDEDNESS: Right SCARS: 2" forehead, left parietal 1" left knee 1/2" right temporal HEALED FRACTURES: None listed PECULIARITIES: None listed	

Reviewed by DPAA IAW DoDM 5400.07 and P.L. 102-190, 105 Stat. 1290, 1480-1481 Date: 12 Mar 2024 Initials: RW

MISMATCH

QC'd by DPAA Date: 21 Mar 2024 Initials: CG

PHYSICAL AND DENTAL COMPARISON CHART

REFNO: 0093



REMAINS OF CILHI 0036-86		NAME AMSPACHER, William H., Jr. 555-64-1641 ATR3 USN	
1	O-AM	<input checked="" type="checkbox"/>	
2	O-AM	2	O-AM, O-AM
3	O-AM, F-AM, L-AM	3	O-AM, O-AM
4	MO-AM	4	
5	MOD-AM	5	
6	M-Sil, D-Sil	6	
7	L-AM	7	M-Sil
8	M-Sil, D-Sil, L-AM	8	D-Sil
9	PX	9	D/F-Sil
10	ML-Sil, D-Sil, L-AM	10	
11	M-Sil, L-AM	11	
12	O-AM	12	
13	O-AM	13	DO-AM
14	Crown Fx'd, O-Prep	14	O-AM, O-AM, L-AM
15	O-Prep, O-Prep	15	
16		<input checked="" type="checkbox"/>	
17	Horizontal impaction	17	Impaction (Mesioangular)
18	O-AM, F-AM, F-AM	18	O-AM
19	MO-AM, F-AM	19	O-AM
20	MOD-AM	20	
21		21	
22		22	
23		23	
24		24	
25	PX	25	
26		26	
27		27	
28	O-AM	28	
29	O-AM	29	
30	MOF-AM, F-AM	30	O-AM, F-AM
31	O-AM, F-AM	31	O-AM
32	Horizontal impaction	32	Impaction (Horizontal)
ESTIMATED HEIGHT 67.2 + 1.2"		HEIGHT 70"	
XXXXXXXXXXXX MUSCULARITY: Slight-average		WEIGHT 170 lb BUILD: Medium	
ESTIMATED AGE 22 - 25 years		AGE 20yrs, 10mos, 06dys DOI: 02 Jun 65 DOB: 26 Jul 44	
HAIR None found		HAIR Brown	
REMARKS RACE: Caucasoid SEX: Male HANDEDNESS: Left HEALED FRACTURES: None observed PATHOLOGIES: Possible healed trauma on Rt frontal above orbit PECULIARITIES: Septal deviation		REMARKS RACE: Caucasian SEX: Male BLOOD TYPE: A Pos HANDEDNESS: Not listed SCARS: Rm left side face Rm right side face Ps sternum Rm right epigastric Rm left subscapular HEALED FRACTURES: Arm & wrist - 7 yrs of age PECULIARITIES: None listed	
<div style="border: 1px solid black; padding: 2px;"> Reviewed by DPAA IAW DoDM 5400.07 and P.L. 102-190, 105 Stat. 1290, 1480-1481 Date: 12 Mar 2024 Initials: RW </div>		<div style="border: 1px solid black; padding: 2px;"> QC'd by DPAA Date: 21 Mar 2024 Initials: CG </div>	

MISMATCH

PHYSICAL AND DENTAL COMPARISON CHART

REFNO: 0093



REMAINS OF		NAME	
CILHI 0036-86		ROMANO, Gerald M. 094-32-1997 LTJG USN	
1	O-AM	<input checked="" type="checkbox"/>	
2	O-AM	2	MODFL-AM
3	O-AM, F-AM, L-AM	3	MODF-AM
4	MO-AM	4	MOD-AM
5	MOD-AM	5	MOD-AM
6	M-Sil, D-Sil	6	M-Sil, D-AM, F-Sil
7	L-AM	7	L-AM, M-Sil
8	M-Sil, D-Sil, L-AM	8	
9	PX	9	M-Sil
10	ML-Sil, D-Sil, L-AM	10	L-AM
11	M-Sil, L-AM	11	D-Sil
12	O-AM	12	MOD-AM, F-Sil
13	O-AM	13	MOD-AM
14	Crown Fx'd, O-Prep	14	MOF-AM, OL-AM
15	O-Prep, O-Prep	15	DOF-AM, L-AM
16		<input checked="" type="checkbox"/>	
17	Horizontal impaction	17	O-AM
18	O-AM, F-AM, F-AM	18	MO-AM, F-AM, DOF-AM
19	MO-AM, F-AM	19	MOD-AM, F-AM, F-AM
20	MOD-AM	20	MOD-AM
21		21	DO-AM
22		22	
23		23	
24		24	
25	PX	25	
26		26	
27		27	
28	O-AM	28	DO-AM
29	O-AM	29	MOD-AM
30	MOF-AM, F-AM	30	MOD-AM, F-AM, L-AM, L-AM
31	O-AM, F-AM	31	MO-AM, DO-AM, F-AM, L-AM
32	Horizontal impaction	32	O-AM
ESTIMATED HEIGHT 67.2 + 1.2"		HEIGHT 72"	
XXXXXXXXXXXX MUSCULARITY: Slight-average		WEIGHT 176 lb BUILD: Medium	
ESTIMATED AGE 22 - 25 years		AGE 23yrs, 02mos, 12dys DOI: 02 Jun 65 DOB: 20 Mar 42	
HAIR None found		HAIR Black	
REMARKS RACE: Caucasoid SEX: Male HANDEDNESS: Left HEALED FRACTURES: None observed PATHOLOGIES: Possible healed trauma on: Rt frontal above orbit PECULIARITIES: Septal deviation		REMARKS RACE: Caucasian SEX: Male BLOOD TYPE: A Pos HANDEDNESS: Not listed SCARS: 1/2" left cheek 2" RLQ VA upper left arm HEALED FRACTURES: None listed PECULIARITIES: None listed	
Reviewed by DPAA IAW DoDM 5400.07 and P.L. 102-190, 105 Stat. 1290, 1480-1481 Date: 12 Mar 2024 Initials: RW		QC'd by DPAA Date: 21 Mar 2024 Initials: CG	

REPRODUCTION

PHYSICAL AND DENTAL COMPARISON CHART

REFNO: 0093



REMAINS OF		NAME	
CILHI 0036-86		PLANTS, Thomas L. 286-34-7998 ATN3 USN	
1	O-AM	1	Drift
2	O-AM	<input checked="" type="checkbox"/>	EXT
3	O-AM, F-AM, L-AM	3	MODL-AM, F-AM
4	MO-AM	<input checked="" type="checkbox"/>	EXT
5	MOD-AM	<input checked="" type="checkbox"/>	EXT
6	M-Sil, D-Sil	6	Tr Pr Dtr for 4,5,7,8
7	L-AM	<input checked="" type="checkbox"/>	EXT
8	M-Sil, D-Sil, L-AM	<input checked="" type="checkbox"/>	EXT
9	PX	9	M-Sil, D-Sil
10	ML-Sil, D-Sil, L-AM	10	F-Sil, D-Sil
11	M-Sil, L-AM	11	F-Sil, M-Sil
12	O-AM	12	DO-AM
13	O-AM	13	MOD-AM
14	Crown Fx'd, O-Prep	14	MODL-AM, F-AM
15	O-Prep, O-Prep	<input checked="" type="checkbox"/>	EXT
16		16	Drift
17	Horizontal impaction	17	Drift
18	O-AM, F-AM, F-AM	<input checked="" type="checkbox"/>	EXT
19	MO-AM, F-AM	19	MO-AM, F-AM, F-AM, DO-AM
20	MOD-AM	<input checked="" type="checkbox"/>	EXT
21		<input checked="" type="checkbox"/>	EXT
22		22	F-AM
23		23	D-AM
24		24	
25	PX	25	
26		26	
27		27	F-AM
28	O-AM	28	DO-AM
29	O-AM	<input checked="" type="checkbox"/>	
30	MOF-AM, F-AM	<input checked="" type="checkbox"/>	
31	O-AM, F-AM	31	DOFL-AM, MODFL-AM
32	Horizontal impaction	32	O-AM
ESTIMATED HEIGHT 67.2 + 1.2"		HEIGHT 68"	
MUSCULARITY: Slight-average		WEIGHT 160 lb BUILD: Medium	
ESTIMATED AGE 22 - 25 years		AGE 25yrs, 0mos, 21dys DOI: 02 Jun 65 DOB: 11 May 40	
HAIR None found		HAIR Brown	
REMARKS RACE: Caucasoid SEX: Male HANDEDNESS: Left HEALED FRACTURES: None observed PATHOLOGIES: Possible healed trauma on Rt frontal above orbit PECULIARITIES: Septal deviation		REMARKS RACE: Caucasian SEX: Male BLOOD TYPE: A Pos HANDEDNESS: Right SCARS: None listed HEALED FRACTURES: None listed PECULIARITIES: Pes planus 2°	

Reviewed by DPAA IAW DoDM 5400.07 and P.L. 102-190, 105 Stat. 1290, 1480-1481 Date: 12 Mar 2024 Initials: RW

MIC MATCH

QC'd by DPAA Date: 21 Mar 2024 Initials: CG

PHYSICAL AND DENTAL COMPARISON CHART

REFNO: 0067



REMAINS OF CILHI 0036-86		NAME DRAEGER, Walter F., Jr. 391-30-2121 Capt USAF	
1	O-AM	<input checked="" type="checkbox"/>	EXT (04 Dec 63)
2	O-AM	2	MO-AM, O-AM
3	O-AM, F-AM, L-AM	3	MOD-AM
4	MO-AM	4	DO-AM
5	MOD-AM	5	O-AM
6	M-Sil, D-Sil	6	M-Sil, LI-AM
7	L-AM	7	M-Sil
8	M-Sil, D-Sil, L-AM	8	M-Sil, D-Sil
9	PX	9	M-Sil, D-Sil
10	ML-Sil, D-Sil, L-AM	10	D-Sil
11	M-Sil, L-AM	11	MI-AM
12	O-AM	12	O-AM
13	O-AM	13	MOD-AM
14	Crown Fx'd, O-Prep	14	MOD-AM, O-AM
15	O-Prep, O-Prep	15	MOD-AM
16		<input checked="" type="checkbox"/>	EXT (04 Dec 63)
17	Horizontal impaction	<input checked="" type="checkbox"/>	EXT (18 Nov 63)
18	O-AM, F-AM, F-AM	18	MO-AM
19	MO-AM, F-AM	19	MOD-AM, F-AM, OL-AM
20	MOD-AM	20	DO-AM
21		21	Rotated
22		22	LI-AM
23		23	
24		24	
25	PX	25	
26		26	
27		27	LI-AM
28	O-AM	28	
29	O-AM	29	MOD-AM
30	MOF-AM, F-AM	30	DO-AM, OL-AM
31	O-AM, F-AM	31	MO-AM
32	Horizontal impaction	<input checked="" type="checkbox"/>	EXT (21 Oct 63)
ESTIMATED HEIGHT 67.2 + 1.2"		HEIGHT 72"	
XXXXXXXXXXXX MUSCULARITY: Slight-average		WEIGHT 160 lb BUILD: Medium	
ESTIMATED AGE 22 - 25 years		AGE 31yrs, 06mos, 06dys DOI: 04 Apr 65 DOB: 28 Sep 33	
HAIR None found		HAIR Brown	
REMARKS RACE: Caucasoid SEX: Male HANDEDNESS: Left HEALED FRACTURES: None observed PATHOLOGIES: Possible healed trauma on Rt frontal above orbit PECULIARITIES: Septal deviation		REMARKS RACE: Caucasian SEX: Male BLOOD TYPE: O Pos HANDEDNESS: Right SCARS: 5" surgical - RLQ HEALED FRACTURES: None listed PECULIARITIES: None listed	
<div style="border: 1px solid black; padding: 2px;"> Reviewed by DPAA IAW DoDM 5400.07 and P.L. 102-190, 105 Stat. 1290, 1480-1481 Date: 12 Mar 2024 Initials: RW </div>		<div style="font-size: 2em; font-weight: bold; opacity: 0.5;">MISMATCH</div>	
<div style="border: 1px solid black; padding: 2px;"> QC'd by DPAA Date: 21 Mar 2024 Initials: CG </div>			

PHYSICAL AND DENTAL COMPARISON CHART

REFNO: 1789



REMAINS OF CILHI 0036-86		NAME KOONS, Dale F. 275-46-8109 Capt USAF	
1	O-AM	X	EXT (13 Oct 71) Pos root tip Lt during EXT
2	O-AM	2	O-AM
3	O-AM, F-AM, L-AM	3	O-AM, O-AM
4	MO-AM	4	
5	MOD-AM	5	
6	M-Sil, D-Sil	6	
7	L-AM	7	
8	M-Sil, D-Sil, L-AM	8	
9	PX	9	
10	ML-Sil, D-Sil, L-AM	10	
11	M-Sil, L-AM	11	
12	O-AM	12	
13	O-AM	13	
14	Crown Fx'd, O-Prep	14	MO-AM, O-AM
15	O-Prep, O-Prep	15	O-AM
16		16	
17	Horizontal impaction	17	
18	O-AM, F-AM, F-AM	18	O-AM
19	MO-AM, F-AM	19	MO-AM
20	MOD-AM	20	
21		21	
22		22	
23		23	
24		24	
25	PX	25	
26		26	
27		27	
28	O-AM	28	
29	O-AM	29	
30	MOF-AM, F-AM	30	O-AM
31	O-AM, F-AM	31	O-AM
32	Horizontal impaction	32	
ESTIMATED HEIGHT 67.2 + 1.2"		HEIGHT 69"	
MUSCULARITY: Slight-average		BUILD: Medium/Heavy	
ESTIMATED AGE 22 - 25 years		AGE 25yrs, 0mos, 13dys	
HAIR None found		HAIR Brown	
REMARKS RACE: Caucasoid SEX: Male HANDEDNESS: Left HEALED FRACTURES: None observed PATHOLOGIES: Possible healed trauma on Rt frontal above orbit PECULIARITIES: Septal deviation		REMARKS RACE: Caucasian SEX: Male BLOOD TYPE: O Pos HANDEDNESS: Left SCARS: 6" vertical - RLQ HEALED FRACTURES: None listed PECULIARITIES: None listed	
<div style="border: 1px solid black; padding: 2px;"> Reviewed by DPAA IAW DoDM 5400.07 and P.L. 102-190, 105 Stat. 1290, 1480-1481 Date: 12 Mar 2024 Initials: RW </div>		<div style="border: 1px solid black; padding: 2px;"> QC'd by DPAA Date: 21 Mar 2024 Initials: CG </div>	

ASSIGNATION

PHYSICAL AND DENTAL COMPARISON CHART

REFNO: 1789



REMAINS OF		NAME	
CILHI 0036-86		STOLZ, Lawrence G. 316-46-4799 Maj USAF	
1	O-AM	<input checked="" type="checkbox"/>	EXT (26 May 71)
2	O-AM	2	O-AM, O-AM
3	O-AM, F-AM, L-AM	3	
4	MO-AM	4	DO-AM
5	MOD-AM	5	
6	M-Sil, D-Sil	6	
7	L-AM	7	
8	M-Sil, D-Sil, L-AM	8	D-Sil
9	PX	9	
10	ML-Sil, D-Sil, L-AM	10	
11	M-Sil, L-AM	11	
12	O-AM	12	
13	O-AM	13	
14	Crown Fx'd, O-Prep	14	O-AM, O-AM
15	O-Prep, O-Prep	15	
16		<input checked="" type="checkbox"/>	EXT (26 May 71)
17	Horizontal impaction	<input checked="" type="checkbox"/>	EXT (26 May 71)
18	O-AM, F-AM, F-AM	18	O-AM
19	MO-AM, F-AM	19	MO-AM
20	MOD-AM	20	
21		21	
22		22	
23		23	
24		24	
25	PX	25	
26		26	
27		27	
28	O-AM	28	
29	O-AM	29	
30	MOF-AM, F-AM	30	MO-AM, O-AM
31	O-AM, F-AM	31	F-AM, O-AM
32	Horizontal impaction	<input checked="" type="checkbox"/>	EXT (26 May 71)
ESTIMATED HEIGHT 67.2 + 1.2"		HEIGHT 70"	
MUSCULARITY: Slight-average		WEIGHT 170 lb BUILD: Medium	
ESTIMATED AGE 22 - 25 years		AGE 26yrs, 01mo, 02dys DOI: 26 Dec 71 DOB: 24 Nov 45	
HAIR None found		HAIR Blond	
REMARKS RACE: Caucasoid SEX: Male HANDEDNESS: Left HEALED FRACTURES: None observed PATHOLOGIES: Possible healed trauma on Rt frontal above orbit PECULIARITIES: Septal deviation		REMARKS RACE: Caucasian SEX: Male BLOOD TYPE: O Neg HANDEDNESS: Right SCARS: None listed HEALED FRACTURES: None listed PECULIARITIES: Pes planus, bilateral, mild	

Reviewed by DPAA IAW DoDM 5400.07 and P.L. 102-190, 105 Stat. 1290, 1480-1481 Date: 12 Mar 2024 Initials: RW

QC'd by DPAA Date: 21 Mar 2024 Initials: CG

PHYSICAL AND DENTAL COMPARISON CHART

REFNO: 0578



REMAINS OF		NAME	
CILHI 0036-86		HOGAN, Jerry F. 424-48-7435 LTJG USN	
1	O-AM	1	O-AM
2	O-AM	2	MO-AM
3	O-AM, F-AM, L-AM	3	DO-AM, MO-AM, F-AM, L-AM
4	MO-AM	4	MOD-AM
5	MOD-AM	5	DO-AM
6	M-Sil, D-Sil	6	M-Sil
7	L-AM	7	D-Sil, M-Sil
8	M-Sil, D-Sil, L-AM	8	M-Sil, D-Sil
9	PX	9	D-Sil, M-Sil
10	ML-Sil, D-Sil, L-AM	10	M-Sil, L-AM (2D-Sil)
11	M-Sil, L-AM	11	
12	O-AM	12	MOD-AM
13	O-AM	13	O-AM
14	Crown Fx'd, O-Prep	14	DO-AM, MOL-AM
15	O-Prep, O-Prep	15	MO-AM
16		16	O-AM, O-AM
17	Horizontal impaction	17	
18	O-AM, F-AM, F-AM	18	DO-AM, MO-AM
19	MO-AM, F-AM	19	EXT, S.C.
20	MOD-AM	20	DO-AM, rotated distally ↑ Drift 5 mm space
21		21	
22		22	
23		23	
24		24	
25	PX	25	
26		26	
27		27	
28	O-AM	28	3 mm space
29	O-AM	29	DO-AM ↓ Drift
30	MOF-AM, F-AM	30	SC
31	O-AM, F-AM	31	MO-AM, OF-AM
32	Horizontal impaction	32	O-AM
ESTIMATED HEIGHT 67.2 + 1.2"		HEIGHT 71" SITTING HEIGHT: 38.2"	
MUSCULARITY: Slight-average		WEIGHT 161 lb BUILD: Medium	
ESTIMATED AGE 22 - 25 years		AGE 26yrs, 10mo, 23dys DOI: 21 Jan 67 DOB: 28 Feb 40	
HAIR None found		HAIR Black	
REMARKS RACE: Caucasoid SEX: Male HANDEDNESS: Left HEALED FRACTURES: None observed PATHOLOGIES: Possible healed trauma on Rt frontal above orbit PECULIARITIES: Septal deviation		REMARKS RACE: Caucasian SEX: Male BLOOD TYPE: A Pos HANDEDNESS: Right SCARS: 1/2" right cranial 1/2" right forehead 1/2" right leg 1/2" left thumb Laceration right leg 1963 HEALED FRACTURES: None listed PECULIARITIES: Left septal deviation	

Reviewed by DPAA IAW DoDM 5400.07 and P.L. 102-190, 105 Stat. 1290, 1480-1481 Date: 12 Mar 2024 Initials: RW

QC'd by DPAA Date: 21 Mar 2024 Initials: CG

PHYSICAL AND DENTAL COMPARISON CHART

REFNO 0457 0



REMAINS OF CILHI 0036-86		NAME COAKLEY, William F. 030-24-5468 LCDR USN	
1	O-AM	<input checked="" type="checkbox"/>	EXT (07 May 58)
2	O-AM	2	OL-AM
3	O-AM, F-AM, L-AM	3	MO-AM, O-AM, F/L-AM
4	MO-AM	4	MODL-AM (1 pin)
5	MOD-AM	5	MO-AM, DO-AM
6	M-Sil, D-Sil	6	D-AM
7	L-AM	7	
8	M-Sil, D-Sil, L-AM	8	M-Sil
9	PX	9	M-Sil
10	ML-Sil, D-Sil, L-AM	10	L-AM
11	M-Sil, L-AM	11	D-Sil
12	O-AM	12	DO-AM
13	O-AM	13	MOD-AM
14	Crown Ex'd, O-Prep	14	MO-AM, O-AM
15	O-Prep, O-Prep	15	O-AM, O-AM
16		<input checked="" type="checkbox"/>	EXT (09 May 58)
17	Horizontal impaction	17	Impacted
18	O-AM, F-AM, F-AM	18	O-AM
19	MO-AM, F-AM	19	O-AM
20	MOD-AM	20	O-AM
21		21	O-AM
22		22	
23		23	
24		24	
25	PX	25	
26		26	
27		27	
28	O-AM	28	
29	O-AM	29	DO-AM
30	MOF-AM, F-AM	30	MODF-AM, F-AM
31	O-AM, F-AM	31	O-AM
32	Horizontal impaction	<input checked="" type="checkbox"/>	EXT (26 Aug 65)
ESTIMATED HEIGHT 67.2 + 1.2"		HEIGHT 71.5" SITTING HEIGHT: 37"	
XXXXXXXXXXXX MUSCULARITY: Slight-average		WEIGHT 172 lb BUILD: Medium	
ESTIMATED AGE 22 - 25 years		AGE 33yrs, 01mo, 01dy DOI: 13 Sep 66 DOB: 12 Aug 33	
HAIR None found		HAIR Brown	
REMARKS RACE: Caucasoid SEX: Male HANDEDNESS: Left HEALED FRACTURES: None observed PATHOLOGIES: Possible healed trauma on Rt frontal above orbit PECULIARITIES: Septal deviation		REMARKS RACE: Caucasian SEX: Male BLOOD TYPE: O Pos HANDEDNESS: Right SCARS: V shaped, left frontal HEALED FRACTURES: Left occipito-parietal Left clavicle Left ribs PECULIARITIES: None listed	

Reviewed by DPAA IAW DoDM 5400.07 and P.L. 102-190, 105 Stat. 1290, 1480-1481 Date: 12 Mar 2024 Initials: RW

MILITARY MATCH

QC'd by DPAA Date: 21 Mar 2024 Initials: CG

PHYSICAL AND DENTAL COMPARISON CHART

REFNO:

(b)(3):P. L. 102-190 105

REMAINS OF		NAME	
		(b)(3):P. L. 102-190 105 Stat. 1290 1480-1481	
1		1	
2		2	
3		3	
4		4	
5		5	
6		6	
7		7	
8		8	
9		9	
10		10	
11		11	
12		12	
13		13	
14		14	
15		15	
16		16	
17		17	
18		18	
19		19	
20		20	
21		21	
22		22	
23		23	
24		24	
25		25	
26		26	
27		27	
28		28	
29		29	
30		30	
31		31	
32		32	
ESTIMATED HEIGHT		HEIGHT	
ESTIMATED WEIGHT		WEIGHT	
ESTIMATED AGE		AGE	
HAIR		HAIR	
REMARKS		REMARKS	
		(b)(3):P. L. 102-190 105 Stat. 1290 1480-1481	
Reviewed by DPAA IAW DoDM 5400.07 and P.L. 102-190, 105 Stat. 1290, 1480-1481 Date: 12 Mar 2024 Initials: RW		QC'd by DPAA Date: 21 Mar 2024 Initials: CG	

REPRODUCED AT GOVERNMENT EXPENSE

REF NO: 0092 1 01
ACC NO: 6006

BIOGRAPHIC DATA SHEET

REPRODUCED AT GOVERNMENT EXPENSE

NAME: CHRISTIAN, David M.
GRADE: LTJG/02
SSN: 571-56-3259
SERVICE NO: 674340
SERVICE: U.S. Navy
BIRTH DATE: 15 Jan 41
DATE OF DEATH: 02 Jun 65
RACE: Caucasian
SEX: Male
HAIR: Brown
HEIGHT: 66 3/4" (see rmks)
WEIGHT: 125 lb (see rmks)
BLOOD TYPE: O Pos
BUILD: Slender
ABNORMALITIES: None listed
MEDICAL RECORDS: Yes
DENTAL RECORDS: No
DENTAL X-RAYS: No
PHOTOGRAPHS: Yes
CASUALTY REPORTS/INCIDENT REPORTS: Yes
DIA FILE NO: None listed
DD FORM 1300: Yes
DATE OF MISSION: 02 Jun 65
TYPE OF MISSION: Reconnaissance
TYPE OF INCIDENT: Hostile action

Reviewed by DPAA IAW DoDM 5400.07 and
P.L. 102-190, 105 Stat. 1290, 1480-1481
Date: 12 Mar 2024 Initials: RW

QC'd by DPAA
Date: 21 Mar 2024
Initials: CG



REF NO: 0092 1 01
ACC NO: 6006

REPRODUCED AT GOVERNMENT EXPENSE

CURRENT STATUS OF INDIVIDUAL: BNR
UNIT ASSIGNED TO: VA-23 USS Midway CVA-41
DUTY POSITION: Pilot
NUMBER OF MIS/BNR: 1 BNR
NAME OF POW CAMP: None listed
TYPE OF LOCATION OF SITE: Secondary location (burial site)
INCIDENT LOCATION: UTM G.C. WG 919 815
LAST KNOWN LOCATION: UTM G.C. WG 921 815
COUNTRY: North Vietnam
PROVINCE: Thanh Hoa
MILITARY REGION: 3
VEHICLE: A-4E
YEAR OF VEHICLE: Not listed
TAIL NO./SERIAL NO. OF VEHICLE: 151144
MISSION CODE NAME/NO: Recon
CALL SIGN: Law Case
TYPE OF INDIVIDUAL WEAPON: None listed
INDIVIDUAL WEAPON SERIAL NO: None listed

REMARKS: The last recorded height and weight for this individual was 68", 130 lb, according to the NAVMED N (Certificate of Death), dated 02 Jun 65. However, it is not known where this information was obtained, nor how accurate it was. Therefore, the recorded height and weight used for David Christian were taken from the Anthropometric Data Form, dated 7 April 1964.



REF NO: 0092 1 01
ACC NO: 6006

SUMMARY OF INCIDENT

On 2 June 1965, Lieutenant Junior Grade David M. CHRISTIAN was the pilot of an A-4E aircraft on a mission over North Vietnam when the aircraft was hit and started to burn. The aircraft impacted the ground in the vicinity of grid coordinates WG 919 815. Witnesses stated that they thought the pilot ejected, but that there was no man-seat separation. A HU-16 aircraft found the wreckage, but no sign of a survivor.

REPRODUCED AT GOVERNMENT EXPENSE

Reviewed by DPAA IAW DoDM 5400.07 and
P.L. 102-190, 105 Stat. 1290, 1480-1481
Date: 12 Mar 2024 Initials: RW

QC'd by DPAA
Date: 21 Mar 2024
Initials: CG



REF NO. 0092 1 01
ACC NO. 6006

INFORMATION CONCERNING PLANE CRASH

AIRCRAFT: A-4E 151144
TYPE TAIL NO.

TIME & DATE: 02 Jun 65
TIME DATE

GRID COORD: UTM G.C. WG 919 815 North Vietnam Thanh Hoa
COORDINATES COUNTRY PROVINCE

REASON FOR CRASH: Aircraft was hit by enemy fire, crashed and burned.

ABOARD: 1 1 BNR 0 0 0
NO. ABOARD NO. KILLED NO. CAPTURED/ NO. WOUNDED NO. MISSING
RELEASED

<u>POSITION ON AIRCRAFT</u>	<u>NAME AND RANK</u>	<u>SN/SSN</u>	<u>UNIT</u>
<u>Pilot</u>	<u>LTJG/02 USN</u> <u>CHRISTIAN, David M.</u>	<u>SN: 674340</u> <u>SSN: 571-56-3259</u>	<u>VA-23</u> <u>USS Midway CVA-41</u>

REPRODUCED AT GOVERNMENT EXPENSE

Reviewed by DPAA IAW DoDM5400.07 and
P.L. 102-190, 105 Stat. 1290, 1480-1481
Date: 12 Mar 2024 Initials: RW

QC'd by DPAA
Date: 21 Mar 2024
Initials: CG

2095 792

DEPARTMENT OF THE ARMY
UNITED STATES ARMY CENTRAL IDENTIFICATION LABORATORY, HAWAII
FORT SHAFTER, HAWAII 96858-5480



REPRODUCED AT GOVERNMENT EXPENSE

DAPC-RED-H

3 April 1986

Special "Bright Light" Research Narrative

SUBJECT:

1. The JCRC "Bright Light" parameters were manually searched in a 20 mile diameter circle utilizing the burial site (G.C. 921 815) of CHRISTIAN, David M., REF NO 0092 1 01, as the base point.
2. The search produced ten additional casualties, whose status is BNR, for possible association with subject remains.

<u>NAME</u>	<u>REF NO</u>	<u>GRID COORDINATES</u>
MCMICAN, "M.D."	0093 1 01	WG 921 815
AMSPACHER, William H., Jr.	0093 1 02	WG 921 815
ROMANO, Gerald M.	0093 1 03	WG 921 815
PLANTS, Thomas L.	0093 1 04	WG 921 815
DRAEGER, Walter F., Jr.	0067 1 01	WG 893 785
KOONS, Dale F.	1789 1 01	WG 876 925
STOLZ, Lawrence G.	1789 1 02	WG 876 925
HOGAN, Jerry F.	0578 0 01	WG 856 691
COAKLEY, William F.	0457 0 01	WG 838 690

(b)(3):P. L. 102-190 105 Stat. 1290 1480-1481

(b)(6)

Chief, Casualty Data Section

Reviewed by DPAA IAW DoDM 5400.07 and
P.L. 102-190, 105 Stat. 1290, 1480-1481
Date: 12 Mar 2024 Initials: RW

QC'd by DPAA
Date: 21 Mar 2024
Initials: CG

SAM SON

CA LAP 0.7

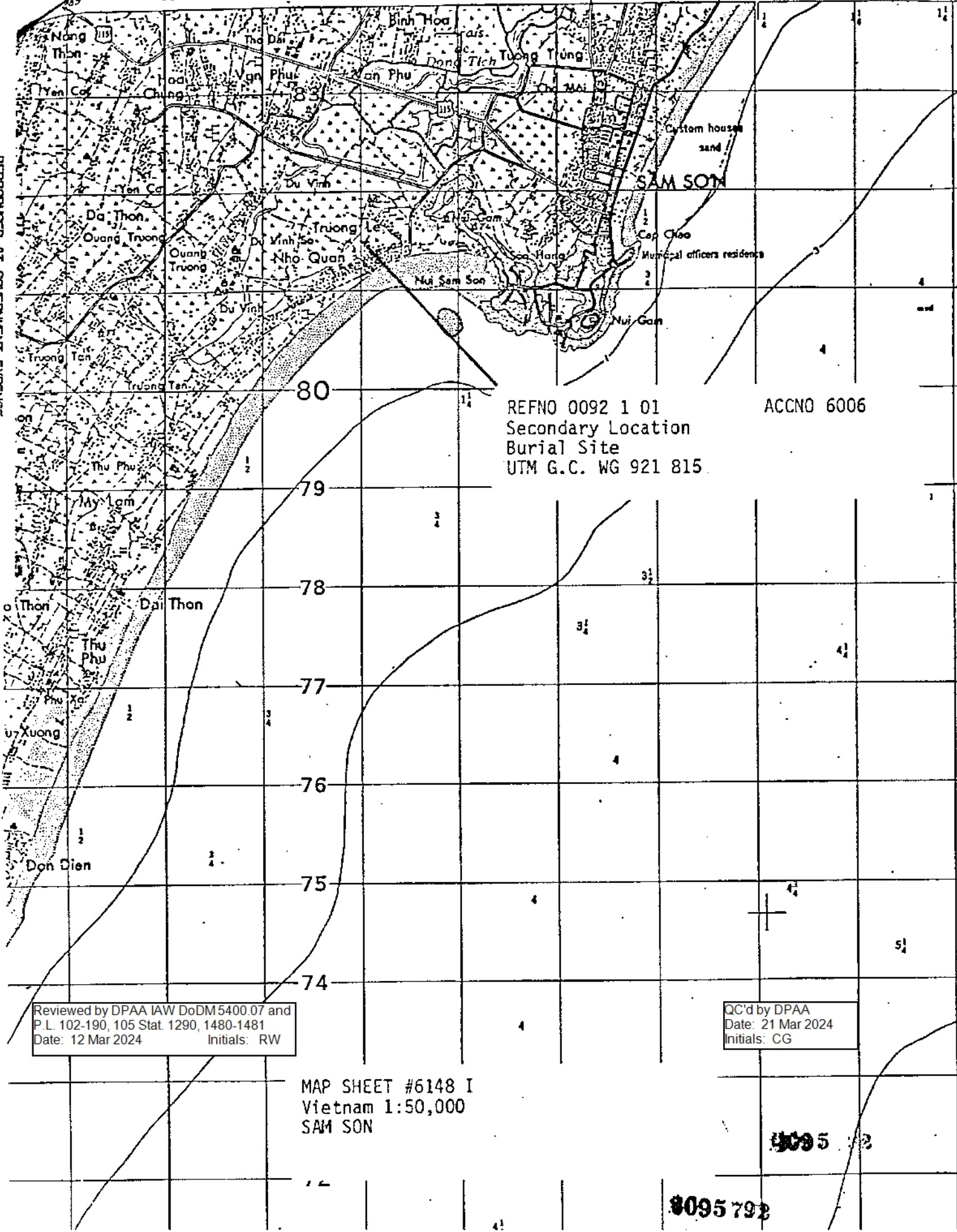
KHU THANH LOC 1.8 KM.



590 591 592 593 594 595 596 597

55'

REPRODUCED AT GOVERNMENT EXPENSE



REFNO 0092 1 01
Secondary Location
Burial Site
UTM G.C. WG 921 815

ACCNO 6006


Reviewed by DPAA IAW DoDM 5400.07 and
P.L. 102-190, 105 Stat. 1290, 1480-1481
Date: 12 Mar 2024 Initials: RW

QC'd by DPAA
Date: 21 Mar 2024
Initials: CG

MAP SHEET #6148 I
Vietnam 1:50,000
SAM SON

8095 792


8095 792



Reviewed by DPAA IAW DoDM 5400.07 and
P.L. 102-190, 105 Stat. 1290, 1480-1481
Date: 12 Mar 2024 Initials: RW

QC'd by DPAA
Date: 21 Mar 2024
Initials: CG

REPRODUCED AT GOVERNMENT EXPENSE



(b)(6)

Reviewed by DPAA IAW DoDM 5400.07 and
P.L. 102-190, 105 Stat. 1290, 1480-1481
Date: 12 Mar 2024 Initials: RW

QC'd by DPAA
Date: 21 Mar 2024
Initials: CG




(b)(6)

DAVID CHRISTIAN
88 - 0036 IHLI

Reviewed by DPAA IAW DoDM 5400.07 and
P.L. 102-190, 105 Stat. 1290, 1480-1481
Date: 12 Mar 2024 Initials: RW

QC'd by DPAA
Date: 21 Mar 2024
Initials: CG

CILHI 0036--86
Possible healed trauma on rt frontal

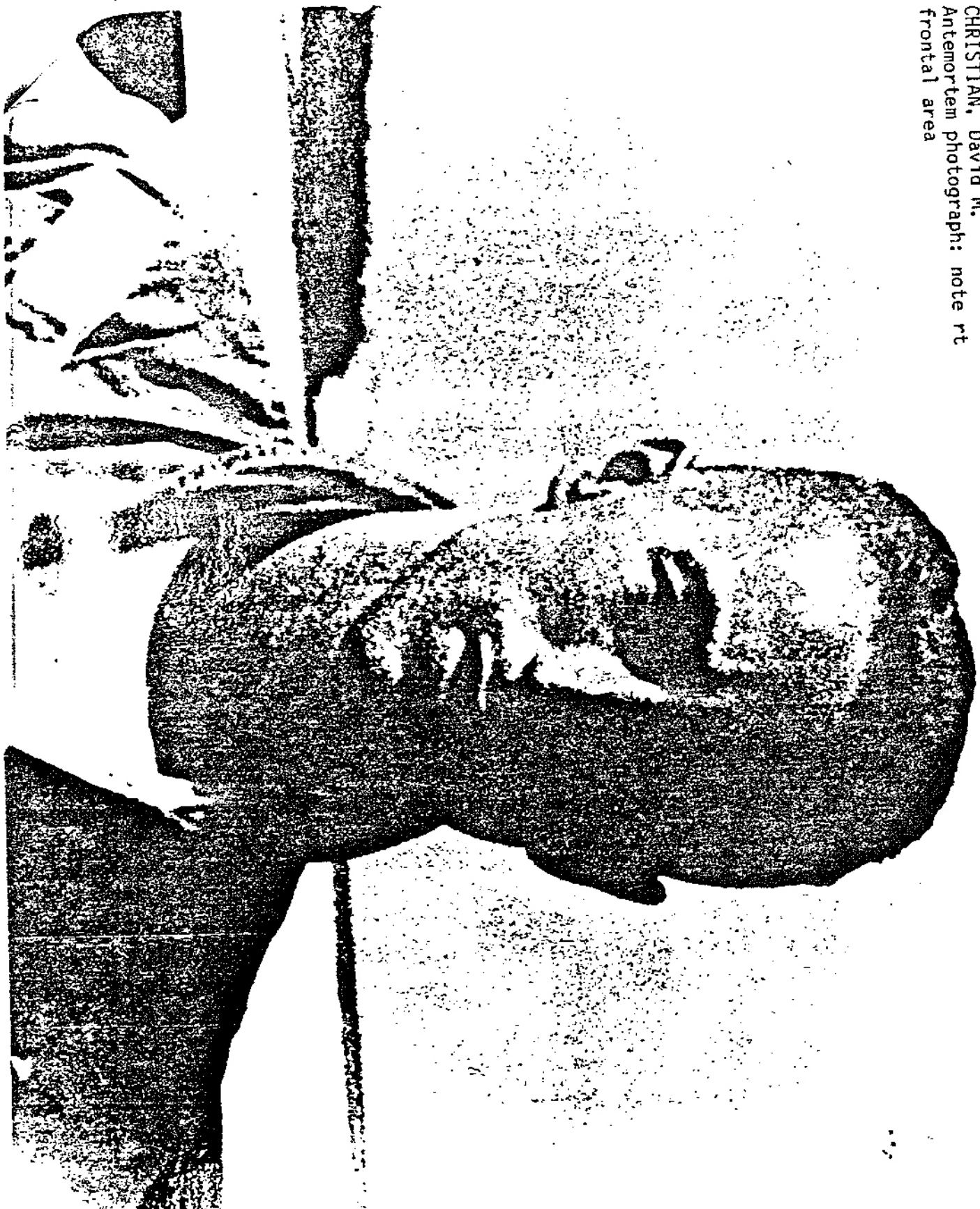

(b)(6)

Reviewed by DPAA IAW DoDM 5400.07 and
P.L. 102-190, 105 Stat. 1290, 1480-1481
Date: 12 Mar 2024 Initials: RW

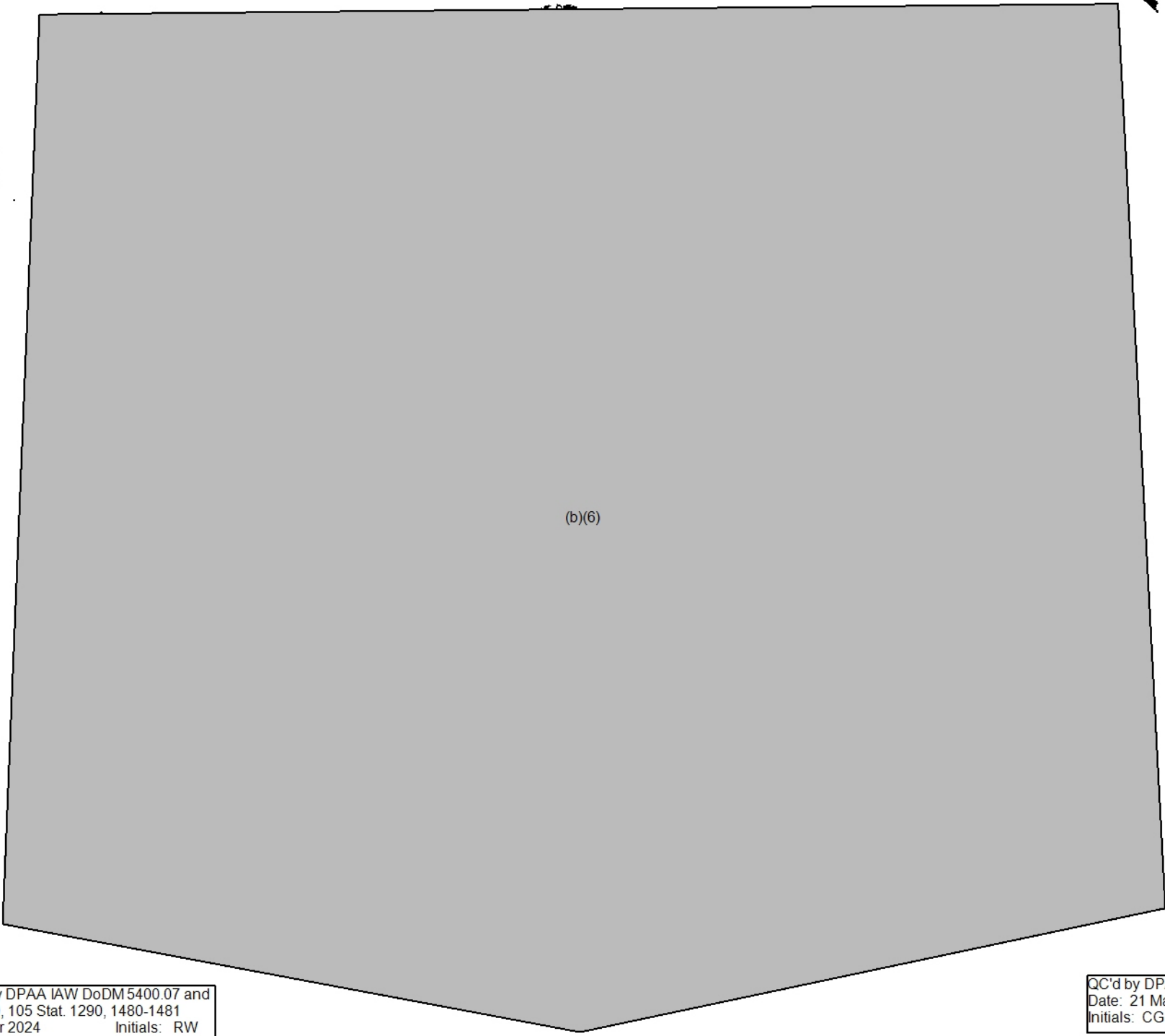
QC'd by DPAA
Date: 21 Mar 2024
Initials: CG

CHRISTIAN, David M.
Antemortem photograph: note rt
frontal area



Reviewed by DPAA IAW DoDM 5400.07 and
P.L. 102-190, 105 Stat. 1290, 1480-1481
Date: 12 Mar 2024 Initials: RW

QC'd by DPAA
Date: 21 Mar 2024
Initials: CG



(b)(6)

CILHI 0036-86
possible healed trauma on rt frontal


Reviewed by DPAA IAW DoDM 5400.07 and
P.L. 102-190, 105 Stat. 1290, 1480-1481
Date: 12 Mar 2024 Initials: RW

QC'd by DPAA
Date: 21 Mar 2024
Initials: CG



ENS David M. CHRISTIAN

Reviewed by DPAA IAW DoDM 5400.07 and
P.L. 102-190, 105 Stat. 1290, 1480-1481
Date: 12 Mar 2024 Initials: RW



(b)(6)

CILHI 0036-86

QC'd by DPAA
Date: 21 Mar 2024
Initials: CG

1. FULL NAME—FIRST NAME—MIDDLE NAME CHRISTIAN, David Marion			2. GRADE AND COMPONENT OF SERVICE AOCCNCPGA, USNR		3. IDENTIFICATION NO. 674340 208 29 24	
4. HOME ADDRESS (Number, street or RFD, city or town, zone and State) P. O. Box 121, Lane, Kansas 9640 LOS COCHES RD, LAKESIDE, CALIF.			5. PURPOSE OF EXAMINATION ENTPE/APPTCO BRANK		6. DATE OF EXAMINATION 15 MAR 1963	
7. SEX Male	8. RACE CAUCASIAN	9. TOTAL YEARS GOVERNMENT SERVICE MILITARY <input type="checkbox"/> CIVILIAN <input type="checkbox"/>		10. AGENCY	11. ORGANIZATION UNIT FF, NAS, Pensacola, Fla.	
12. DATE OF BIRTH 15 JAN 1941		13. PLACE OF BIRTH Oakland, Calif.		14. NAME, RELATIONSHIP, AND ADDRESS OF NEXT OF KIN Jess M. CHRISTIAN, (Father) Same as # 4.		
15. EXAMINING FACILITY OR EXAMINER, AND ADDRESS U. S. Naval SchAvMed, Pensacola, Florida				16. OTHER INFORMATION RELIGION: Protestant (Methodist)		
17. RATING OR SPECIALTY SNA				TIME IN THIS CAPACITY (Total)		LAST SIX MONTHS
				0		0

CLINICAL EVALUATION

NOR- MAL	(Check each item in appropriate column; enter "NE" if not evaluated.)	ABNOR- MAL
X	18. HEAD, FACE, NECK, AND SCALP	
X	19. NOSE	
X	20. SINUSES	
X	21. MOUTH AND THROAT	
X	22. EARS—GENERAL (Int. & ext. canals) (Auditory acuity under items 70 and 71)	
X	23. DRUMS (Perforation)	
X	24. EYES—GENERAL (Visual acuity and refraction under items 68, 69 and 67)	
X	25. OPHTHALMOSCOPIC	
X	26. PUPILS (Equality and reaction)	
X	27. OCULAR MOTILITY (Associated parietal movements, nystagmus)	
X	28. LUNGS AND CHEST (Include breaths)	
	29. HEART (Thrust, size, rhythm, sounds)	X
X	30. VASCULAR SYSTEM (Varicosities, etc.)	
X	31. ABDOMEN AND VISCERA (Include hernia)	
	32. ANUS AND RECTUM (Hemorrhoids, fistulae) (Treatise, if indicated)	X
X	33. ENDOCRINE SYSTEM	
X	34. G-U SYSTEM	
X	35. UPPER EXTREMITIES (Strength, range of motion)	
X	36. FEET	
X	37. LOWER EXTREMITIES (Except feet) (Strength, range of motion)	
X	38. SPINE, OTHER MUSCULOSKELETAL	
	39. IDENTIFYING BODY MARKS, SCARS, TATTOOS	X
X	40. SKIN, LYMPHATICS	
X	41. NEUROLOGIC (Equilibrium tests under item 72)	
X	42. PSYCHIATRIC (Specify any personality deviation)	
	43. PELVIC (Females only) (Check how done)	
	<input type="checkbox"/> VAGINAL <input type="checkbox"/> RECTAL	

NOTES. (Describe every abnormality in detail. Enter pertinent item number before each comment. Continue in item 73 and use additional sheets if necessary.)

AERONAUTICAL ADAPTABILITY: Favorable
SELF BALANCE TEST: Steady

#39: MARKS AND SCARS:

ANT: Circ.
S 1 1/2" Rt. Patellar
POST: VSULD
S 1" Occipital
S 1" Rt. Elbow

25 APR 1963

Exam: Chief, BuMed
By: BuPers

Is Forwarded considered
Physically qualified.

H. A. BAKER
By Direction

(Continue in item 73)

44. DENTAL (Place appropriate symbols above or below number of upper and lower teeth, respectively.)																REMARKS AND ADDITIONAL DENTAL DEFECTS AND DISEASES			
O—Restorable teeth —Nonrestorable teeth X—Missing teeth XXX—Replaced by dentures (6 X 4)—Fixed bridge, brackets to include abutments																Qualified T-2 C-3			
R	1	2	3	4	5	6	7	8	9	10	11	12	13	14	15			16	L
G	32	31	30	29	28	27	26	25	24	23	22	21	20	19	18			17	E
H	X		O											O					F
T																	T		

LABORATORY FINDINGS

45. URINALYSIS: A. SPECIFIC GRAVITY 1.022				46. CHEST X-RAY (Place, date, film number and result) U. S. Naval SchAvMed, Pensacola, Fla. No: 1256 Neg dtd 15 Mar 1963			
B. ALBUMIN Neg.		D. MICROSCOPIC		47. SEROLOGY (Specify test used and result)		48. EKG	
C. SUGAR Neg.		Ess. Neg.		VDRL: Neg.		WNL	
				49. BLOOD TYPE AND RH FACTOR		50. OTHER TESTS	
				"O"			

SOCIAL SECURITY NO:

Chest Exp: 32 1/2" Insp: 36" MEASUREMENTS AND OTHER FINDINGS Sitting Height: 35 1/4"

51. HEIGHT 67"	52. WEIGHT 123 1/2	53. COLOR HAIR Brown	54. COLOR EYES Brown	55. BUILD: <input checked="" type="checkbox"/> SLENDER <input type="checkbox"/> MEDIUM <input type="checkbox"/> HEAVY <input type="checkbox"/> OBESE	56. TEMPERATURE 98.6	
57. BLOOD PRESSURE (Arm at heart level) CER / 14			58. PULSE (Arm at heart level) Immediately			
A. SITTING	SYS. 116 DIAS. 68	B. RECUMBENT	SYS. 120 DIAS. 74	C. 2 MIN. AFTER	D. RECUMBENT	
100		Ret. 60		76		
E. AFTER STANDING 3 MIN.		80				
59. DISTANT VISION		60. REFRACTION		61. NEAR VISION		
RIGHT 20/	20	CORR. TO 20/	BY	S.	OX	
LEFT 20/	20	CORR. TO 20/	BY	S.	OX	
62. HETEROPHORIA (Specify distance)						
ES°	0.0	EX°	2.0	R. H.	0.0	
L. H.	C.4	PRISM DIV.	20/	PRISM CONV.	CT	
63. ACCOMMODATION		64. COLOR VISION (Test used and result)		65. DEPTH PERCEPTION (Test used and score)		
RIGHT	8.9	LEFT	9.9	FaLant: Passed		
66. FIELD OF VISION		67. NIGHT VISION (Test used and score)		68. RED LENS TEST		
Normal				69. INTRAOCULAR TENSION		
				Normal		
70. HEARING		71. AUDIOMETER				72. PSYCHOLOGICAL AND PSYCHOMOTOR (Tests used and score)
RIGHT WV	15 /15 SV	15 /15	250 870	500 812	1000 1024	
LEFT WV	15 /15 SV	15 /15	2000 2280	4000 4000	6000 6144	
			8000 8192			

73. NOTES (Continued) AND SIGNIFICANT OR INTERVAL HISTORY

No significant history.

BUREAU OF MEDICINE AND SURGERY
 26 APR 1963
 Is physically qualified and aeronautically adapted for duty involving the actual control of aircraft.

C. R. Mc Carl
 C. R. MC CARL
 By direction

(Use additional sheets if necessary)

74. SUMMARY OF DEFECTS AND DIAGNOSES (List diagnoses with item numbers)

29: Pulmonic systolic murmur, grade II of IV, functional. NCD

32: Small external hemorrhoid. NCD

75. RECOMMENDATIONS—FURTHER SPECIALIST EXAMINATIONS INDICATED (Specify)

None

76. A. PHYSICAL PROFILE

P	U	L	H	E	S

B. PHYSICAL CATEGORY

A	B	C	E

77. EXAMINEE (Check) PQ & AA DIACA SNA. PQ for Commissioning. PQ to perform active duty at sea and on foreign service.

78. APPROVAL AND SIGNATURE

79. TYPED OR PRINTED NAME OF PHYSICIAN (b)(6) USN	SIGNATURE
80. TYPED OR PRINTED NAME OF PHYSICIAN	SIGNATURE
81. TYPED OR PRINTED NAME OF DENTIST OR PHYSICIAN (Indicate which) (b)(6) USN	SIGNATURE
82. TYPED OR PRINTED NAME OF REVIEWING OFFICER OR APPROVING AUTHORITY (b)(6) USN	SIGNATURE

NUMBER OF ATTACHED SHEETS

Reviewed by DPAA IAW DoDM 5400.07 and P.L. 102-190, 105 Stat. 1290, 1480-1481
 Date: 31 AUG 2021
 Initials: RW

QC'd by DPAA
 Date: 21 Mar 2024
 Initials: CG